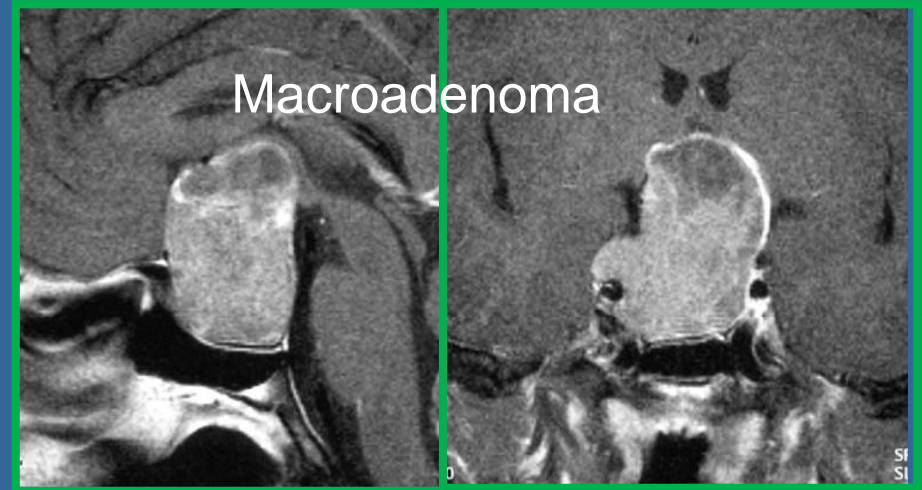
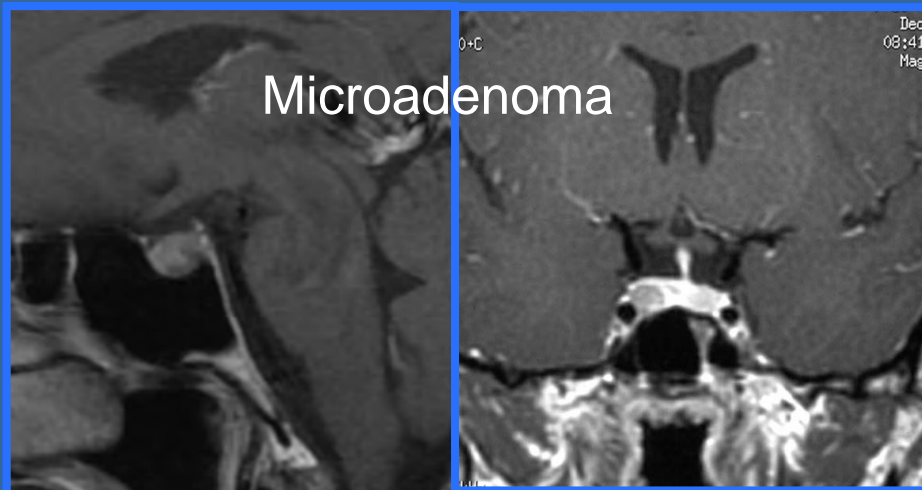


Pituitary Adenomas

Benign tumors of the "master gland"

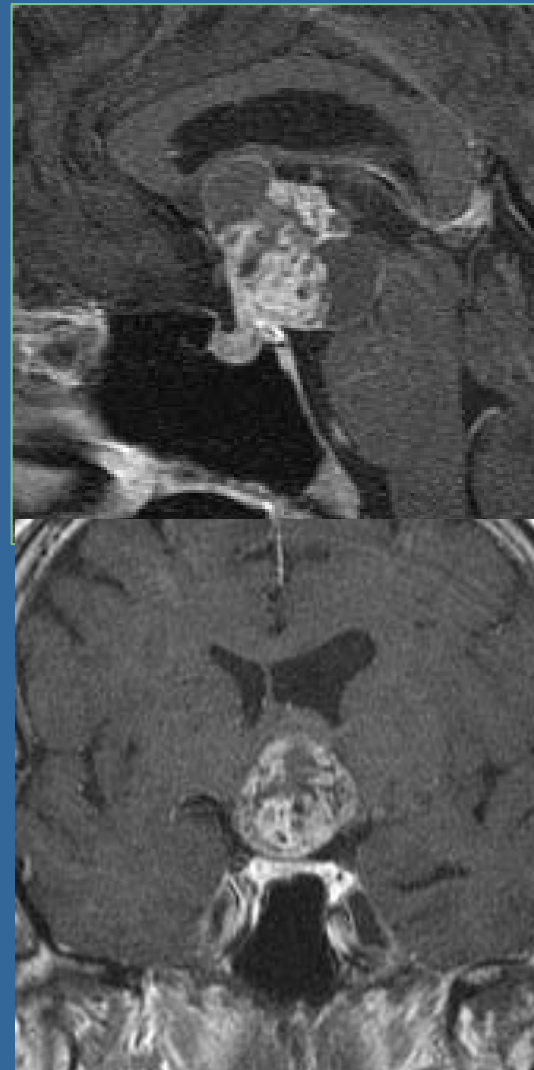
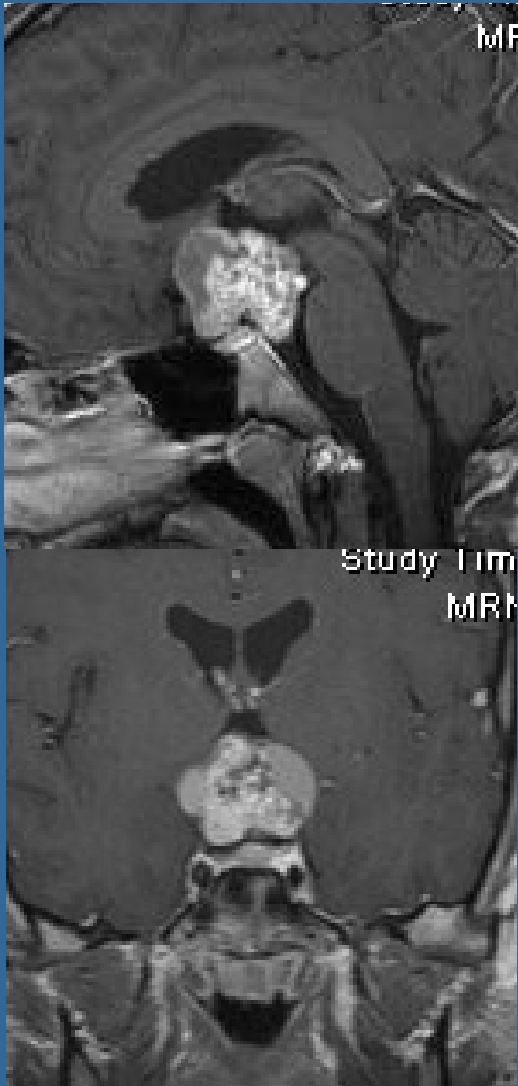


Types

- Acromegaly
- Cushing's Disease
- Prolactinoma
- TSH-oma
- Non-functional

Craniopharyngioma

Two examples of suprasellar solid and cystic craniopharyngiomas causing visual loss and pituitary gland failure



Rathke's Cleft Cyst

Two examples of RCCs causing pituitary hormonal dysfunction and headaches

