A Primer of Brain Tumors

A PATIENT'S REFERENCE MANUAL, 8TH EDITION

A Word About ABTA

Founded in 1973, the not-for-profit American Brain Tumor Association has a proud history of funding research, providing patient services, and educating people about brain tumors. Our mission is to eliminate brain tumors through research and meet the needs of brain tumor patients and their families.

We thank the following for their volunteer assistance in the writing of this publication:

Anthony Asher, MD, Carolina Neurosurgery and Spine Associates, Charlotte, North Carolina; Peter C. Burger, MD, Johns Hopkins Hospital, Department of Pathology, Baltimore, Maryland; Central Brain Tumor Registry of the United States, Chicago, Illinois; David Croteau, MD, NeoPharm, Lake Forest, Illinois; Jillann Demes, MSW, LSW, American Brain Tumor Association; Tom Mikkelsen, MD, Hermelin Brain Tumor Center, Henry Ford Health System, Detroit, Michigan; Teresa E. Omert RN, APN-CNS, Chicago, Illinois; Steven V. Pacia, MD, New York University Comprehensive Epilepsy Center, New York, New York; Nina Paleologos, MD, Feinberg School of Medicine, Northwestern University and Evanston Northwestern Healthcare, Evanston, Illinois; and Jill Barnholtz-Sloan, PhD, Karmanos Cancer Institute and Wayne State University, Detroit, Michigan. We also thank Gail Segal for her tireless contributions to the previous editions of this Primer.

ALL RIGHTS RESERVED.
ISBN 0-944093-69-8
COPYRIGHT © 1978, 1980, 1985, 1988, 1991, 1996, 1998, 2002, 2004 AMERICAN BRAIN TUMOR ASSOCIATION
REPRODUCTION WITHOUT PRIOR WRITTEN PERMISSION IS PROHIBITED.

A Primer of Brain Tumors

A PATIENT'S REFERENCE MANUAL, 8TH EDITION

American Brain Tumor Association

2720 River Road, Suite 146 Des Plaines, Illinois 60018

800.886.2282 TEL info@abta.org EMAIL
847.827.9918 FAX www.abta.org WEB

Dedication

This Primer is dedicated to the memory of Jerome Braverman and Florence Braverman.

Jerome served as president of the Association from 1979 to 1981 and his efforts made the first edition of this publication possible. Active in a variety of civic and charitable causes, Jerry often went out of his way to help those in need. His broad shoulders, patient ear, and soothing voice are missed.

Florence devoted herself to responding personally with notes of thanks to the thousands of people who supported the Association's work with their contributions and good wishes. A caring and generous person, the loss of Florence's kindness and understanding leaves a void that cannot be filled.

This publication was made possible through the generosity of: Bridgesone/Firestone Trust Fund; Byrne Foundation; Chroma Corporation; D. R. Long Foundation; Edmond & Alice Opler Foundation; Employees Community Fund of Boeing California; Guy B. Reno Family Foundation; Howard & Roberta Goss Charitable Foundation; Huizenga Family Foundation, Inc; Land's End Direct Merchants; Lintilhac Foundation, Inc; Maslon Foundation; Morgan Stanley Dean Witter & Co, Inc; Nalco Foundation; OMRON Foundation, Inc; R. S. Byrnes Associates, Inc; Special People in Need; and Transco, Inc. Charitable Foundation. Donations were also received in honor of Nat Mizne, and from Jerry E. Windham in memory of Helga.

Table *of* Contents

Chapter 1
Parts of the Brain 3
TERMINOLOGY 4

Chapter 2
Brain Tumor Basics 8
PRIMARY BRAIN TUMORS 9
METASTATIC BRAIN TUMORS 9
TUMOR NAMES 10
TUMOR GRADING 10
CHANGE OF DIAGNOSIS 11
TUMOR STAGING 11
PROGNOSIS 11
ABOUT "LESIONS" 11

Chapter 3
Facts & Statistics 13
INCIDENCE STATISTICS 14
REGARDING INCIDENCE TRENDS 14
PREVALENCE STATISTICS 14
PEDIATRIC STATISTICS 15
AGE & GENDER-SPECIFIC STATISTICS 15
TUMOR-SPECIFIC STATISTICS 16
SURVIVAL TRENDS 16
SOURCES 17

Chapter 4
Causes & Risk Factors 18
ENVIRONMENTAL FACTORS 19
GENETIC FACTORS 19
QUESTIONS ABOUT HEREDITY 20
MEDLINE SEARCHES 20

Chapter 5
Diagnosis & Follow-Up 21
MAKING A DIAGNOSIS 22
NEUROLOGICAL EXAM 22
SCANS 22
X-RAYS 25
LABORATORY TESTS 25
BIOPSY 26
ABOUT FOLLOW-UP TESTING 26

Chapter 6
Types of Brain & Spinal Cord Tumors 27
ACOUSTIC NEUROMA 28
ASTROCYTOMA 28
ATYPICAL TERATOID RHABDOID TUMOR (ATRT) 32
CHONDROMA 32
CHONDROSARCOMA 32
CHORDOMA 32
CHOROID PLEXUS CARCINOMA 33
CHOROID PLEXUS PAPILLOMA 33
CRANIOPHARYNGIOMA 33
CYSTS 34
DYSEMBRYOPLASTIC NEUROEPITHELIAL TUMOR (DNET) 35
EPENDYMOMA 35
GANGLIOCYTOMA AND GANGLIOGLIOMA 36
GERM CELL TUMORS 36
GERMINOMA 37
GLIOBLASTOMA MULTIFORME (GBM) 37
GLIOMA 39
GLIOMA, BRAIN STEM 39
GLIOMA, MIXED 40
GLIOMA, OPTIC 40
GLIOMATOSIS CEREBRI 41
GLOMUS JUGLARE 41
HEMANGIOBLASTOMA 41
HEMANGIOPERICYTOMA 42
LIPOMA 42
LYMPHOMA 42
MEDULLOBLASTOMA 43
MENINGIOMA 44
METASTATIC BRAIN TUMOR 45
NEUROBLASTOMA, CEREBRAL 45
NEUROCYTOMA, CENTRAL 45
NEUROFIBROMATOSIS (NF) 46
OLIGODENDROGLIOMA 46
PINEAL REGION TUMORS 47
PITUITARY TUMORS 47
PNET (PRIMITIVE NEUROECTODERMAL TUMOR) 48
PSEUDOTUMOR CEREBRI 49
RECURRENT TUMORS 49
SCHWANNOMA 49

Types of Tumors continued on next page

! Please note that the majority of these chapters print in two columns. If you do not see two columns when reading the information please contact the American Brain Tumor Association at 800-886-2282. We can provide an alternative format for you. This publication is also available on our website at *www.abta.org*.

Table *of* Contents *continued*

SKULL BASE TUMORS 49
SPINAL CORD TUMORS 50
TERATOMA 50
TOXOPLASMOSIS 51
TUBEROUS SCLEROSIS (BOURNEVILLE'S DISEASE) 51

Chapter 7
Seizures 52
WHAT ARE SEIZURES? 53
TYPES OF SEIZURES 53
HOW TO HELP SOMEONE DURING A SEIZURE 54
TREATMENT 54
ABOUT ANTIEPILEPTIC DRUG THERAPY . . . 54
SIDE-EFFECTS OF DRUG THERAPY 55
MANAGING COMMON SIDE-EFFECTS 57

Chapter 8
Comfort & Coping 58
UNDERSTANDING YOUR DISEASE 59
TELLING FAMILY AND FRIENDS 59
YOUR FEELINGS 60
LIVING YOUR LIFE 61
COPING WITH STRESS 61
FINDING A SUPPORT GROUP 62

Chapter 9
Questions to Ask 63
TALKING TO YOUR HEALTHCARE TEAM 64
YOUR FIRST VISIT 64
ABOUT INSURANCE 64
SEEING A SPECIALIST 65
FOLLOWING TREATMENT A NEXT STEP 65
LIVING WITH A BRAIN TUMOR 65

Notes 66

Publications & Services . . . Inside Back Cover

THE MATERICAL CONTAINED IN THIS BOOK IS PROVIDED FOR INFORMATIONAL PURPOSES ONLY AND SHOULD NOT BE CONSIDERED AS MEDICAL ADVICE. INCLUSION DOES NOT IMPLY THE AMERICAN BRAIN TUMOR ASSOCIATION'S ENDORSEMENT OR RECOMMENDATION. ALWAYS CHECK WITH YOUR DOCTOR ABOUT YOUR SPECIFIC MEDICAL PROBLEM OR CONDITION. INFORMATION HEREIN IS SUBJECT TO CHANGE.

Sharing knowledge. Sharing hope.

Learning you or your loved one has a tumor in the brain or spine can be very frightening. You may know little about tumors, and even less about the brain. You might be confused about the new terms you are hearing, angry because you need to make decisions you are not prepared for, and dazed by all the changes in your life.

The American Brain Tumor Association wrote this book to help you, your family and your friends learn about brain tumors. We hope this knowledge will offer a degree of comfort and help you feel more in control of your life.

In addition to this publication we offer an extensive library of resource publications and support services. We can be of help, call us at 800-886-2282 or visit our website at www.abta.org.

Chapter 1

Parts of the Brain

Living creatures are made up of cells. Groups of cells, similar in appearance and with the same function, form tissue. The brain is a soft mass of supportive tissues and nerve cells connected to the spinal cord. Nerves in the brain and spinal cord transmit messages throughout the body. The brain and spinal cord together form the central nervous system (CNS).

The central nervous system is the core of our existence. It controls our personality — thoughts, memory, intelligence, speech and understanding, emotions; senses — vision, hearing, taste, smell, touch; basic body functions — breathing, heart beat, blood pressure; and how we function in our environment — movement, balance, and coordination.

Learning about the normal workings of brain and spine will help you understand the symptoms of brain tumors, how they are diagnosed, and how they are treated.

Terminology

Detailed, enlarged diagrams of the brain can be found on page 7.

BASAL GANGLIA

The basal ganglia are masses of nerve cells deep within the cerebral hemispheres.

BRAIN STEM

The brain stem is the bottom-most portion of the brain, connecting the cerebrum with the spinal cord. The midbrain, pons, medulla oblongata and reticular formation are all part of the brain stem.

CEREBELLOPONTINE ANGLE

The angle between the pons and the cerebellum.

CEREBELLUM

The cerebellum is the second largest area of the brain. It consists of two hemispheres, or halves, as well as a middle portion. The cerebellum is connected to the brain stem.

CEREBROSPINAL FLUID (CSF)

CSF is the clear, watery fluid made in the ventricles that bathes and cushions the brain and spinal cord. It circulates through the ventricles and the subarachnoid space.

CSF AND VENTRICLES

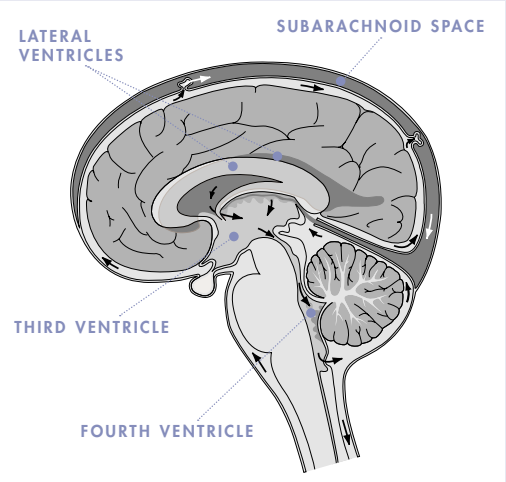

CEREBRUM/CEREBRAL HEMISPHERES

The largest area of the brain is the cerebrum which consists of the right and left hemispheres. In general, the right cerebral hemisphere controls the left side of the body and the left cerebral hemisphere controls the right side of the body.

Each hemisphere is comprised of four sections called lobes: frontal, parietal, temporal, and occipital. Each lobe controls a specific group of activities. The outer layer of the cerebrum is made up of gray matter, which is nerve cells. Nerve cells control brain activity.

The inner portion of the cerebrum is mostly white matter with nerve fibers called axons. These are insulated by a fatty substance known as myelin. White matter carries information between nerve cells by conducting electrical impulses.

MAJOR PARTS OF THE BRAIN

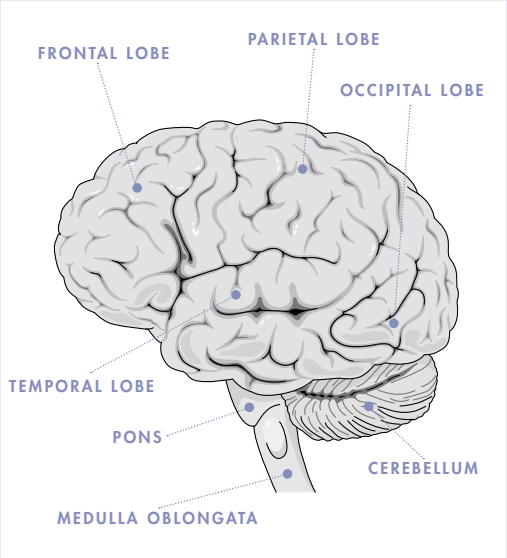

CHOROID PLEXUS

The choroid plexus produces spinal fluid that flows through the ventricles and meninges surrounding the brain and spinal cord.

CORPUS CALLOSUM

The corpus callosum is made of nerve fibers, deep in the brain, that connect the two halves of the cerebral hemispheres.

CRANIAL NERVES

There are 12 pairs of cranial nerves. Their functions are described in the illustration on the following page.

GLIAL TISSUE (NEUROGLIA)

Glia is the supportive tissue of the brain. The cells which make up this tissue are called glial cells. The most common glial cells are astrocytes and oligodendrocytes. Ependymal cells are another form of glia. Unlike nerves,

CRANIAL NERVES *view from bottom of brain*

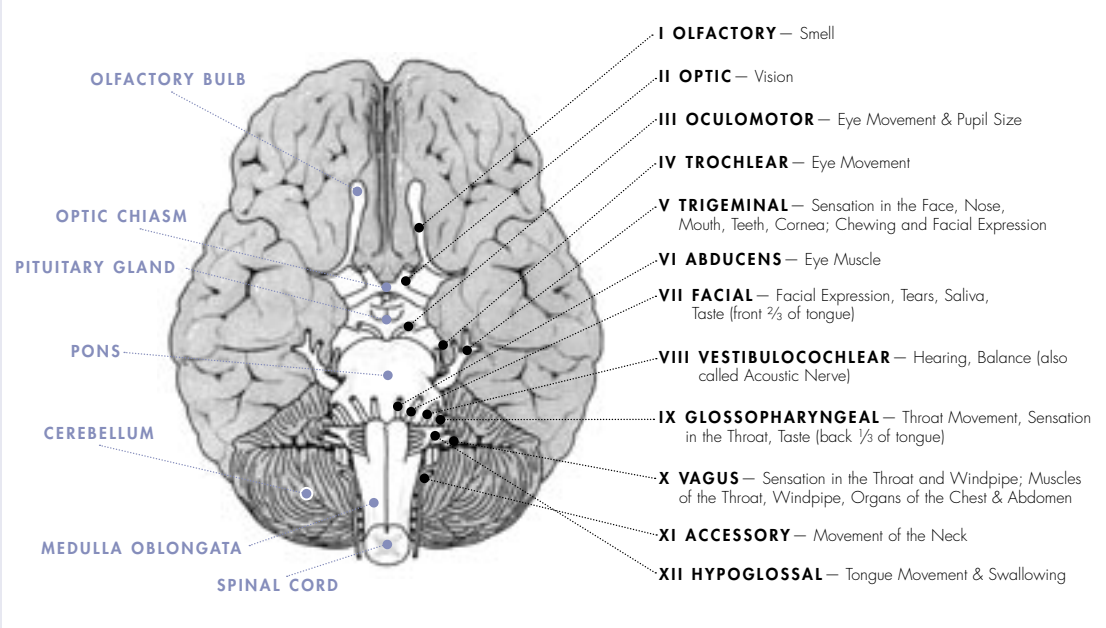

glia can reproduce itself. Glial cells are the origin of the largest percentage of brain tumors, i.e., astrocytomas (including glioblastoma), oligodendrogliomas, and ependymomas. Astrocytes are involved with the blood brain barrier and brain metabolism. Oligodendrocytes maintain the myelin covering of nerve cells. Myelin helps transmit information between nerve cells.

HYPOTHALAMUS

The hypothalamus makes up part of the wall of the third ventricle and is the base of the optic chiasm.

MEDULLA OBLONGATA

The medulla oblongata, a part of the brain stem, connects the brain with the spinal cord. It contains the origins of the 9th, 10th, 11th, and 12th cranial nerves.

MENINGES

The meninges are three membranes that completely cover the brain and the spinal cord. Spinal fluid flows in the space between two of the membranes. A tumor called meningioma arises from the meninges.

MIDBRAIN

The midbrain is the short portion of the brain stem between the pons and the cerebral hemispheres. The top of the midbrain is called the tectum (or tectal area). The 3rd and 4th cranial nerves originate in the midbrain.

OPTIC CHIASM

The optic chiasm is the area under the hypothalamus where each of the two optic nerves crosses over to the opposite side, forming an X shape.

PINEAL GLAND

The pineal gland lies below the corpus callosum. It produces the hormone melatonin. This hormone is believed to control the biological rhythm of the body.

PITUITARY GLAND

The pituitary gland is attached to, and receives messages from, the hypothalamus. The pituitary gland is composed of two lobes — the anterior and the posterior. Several hormones are produced by the pituitary including prolactin, corticotropin, and growth hormone.

THE PITUITARY GLAND

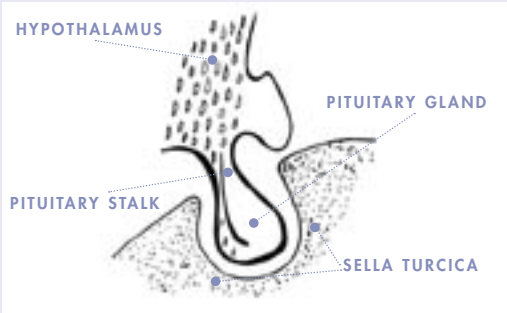

PONS

The pons, a part of the brain stem, contains the origins of the 5th, 6th, 7th, and 8th cranial nerves.

POSTERIOR FOSSA (INFRATENTORIUM)

The tentorium separates the posterior fossa from the cerebral hemispheres. The area *below* the tentorium is called the infratentorium, or the posterior fossa. This area within the skull contains the cerebellum and the brain stem.

The area *above* the tentorium is called the supratentorium.

RETICULAR FORMATION

The reticular formation is the central core of the brain stem. It connects with all parts of the brain and brain stem.

SELLAR REGION (SUPRASELLAR, PARASELLAR)

The sellar region is the area around the sella turcica. The sella turcica is a hollow in the skull bone that contains the pituitary gland.

SKULL BASE

Skull base refers to the bony areas that support the bottom of the frontal lobes, the bottom of the temporal lobes, and the brain stem and cerebellum.

BONES OF THE SKULL

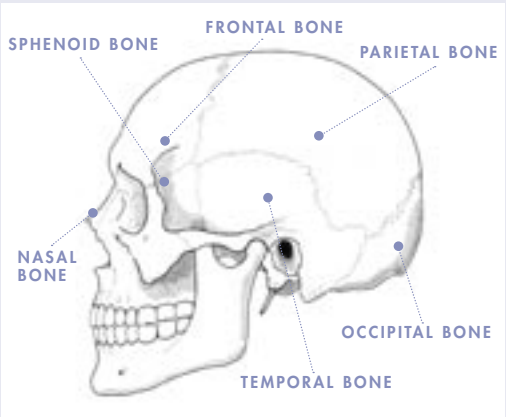

SPINAL CORD

The spinal cord is made up of neurons and their extensions, i.e., nerve fibers. It begins in the medulla oblongata of the brain and continues through the hollow center of the vertebrae (the bones of the spine). The spinal cord is covered by the meninges. Cerebrospinal fluid flows through the meninges.

SUPRATENTORIUM

The supratentorium is the area above the tentorium containing the cerebral hemispheres.

TENTORIUM

The tentorium is a flap of meninges separating the cerebral hemispheres from the structures in the posterior fossa.

THE TENTORIUM

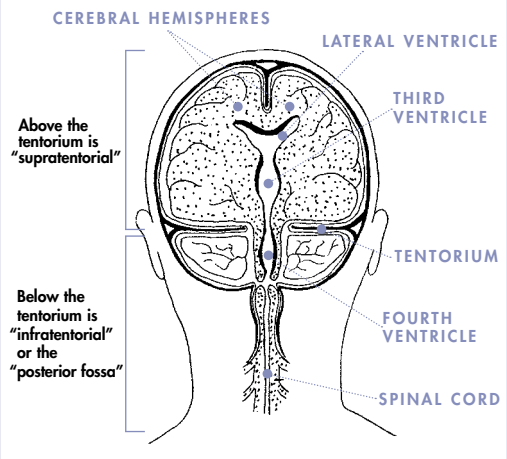

THALAMUS

The thalamus surrounds the third ventricle.

VENTRICLES

These are connected cavities (the lateral, third, and fourth ventricles) that contain cerebrospinal fluid. The fluid is produced by the choroid plexus, and flows through the ventricles and the subarachnoid space of the meninges.

There are two lateral ventricles, one in each cerebral hemisphere. The third ventricle is beneath the corpus callosum and surrounded by the thalamus. The fourth ventricle is an expansion of the central canal of the medulla oblongata.

THE VENTRICLES

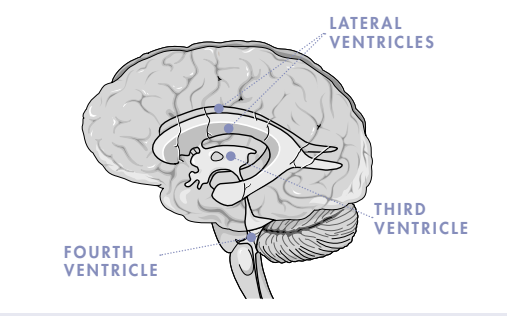

CROSS SECTION OF THE BRAIN

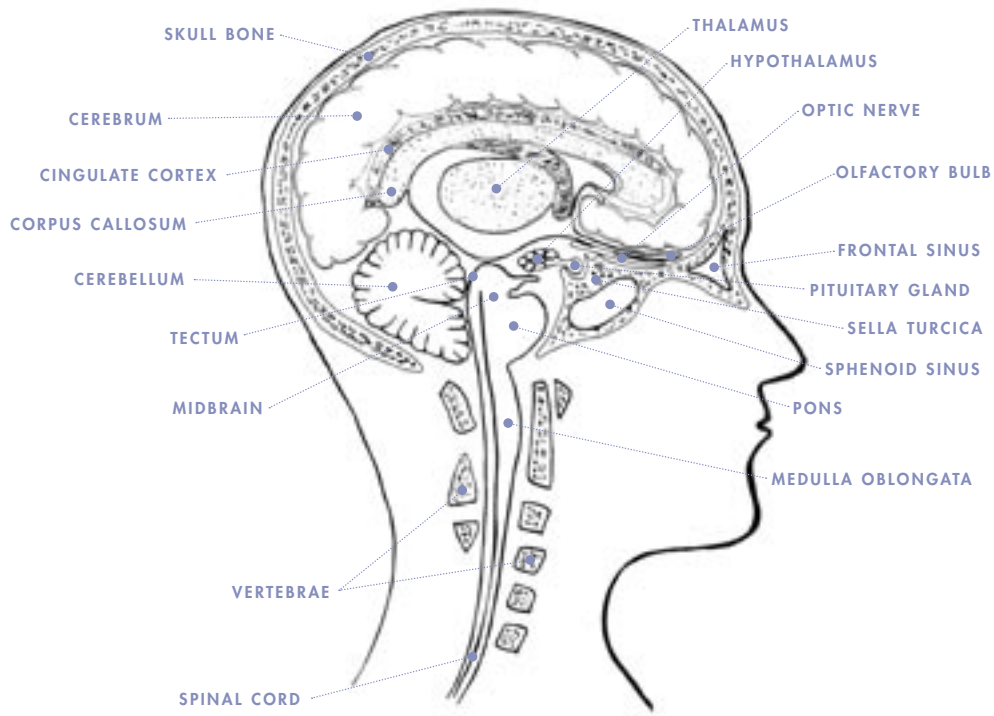

SIDE VIEW OF THE BRAIN

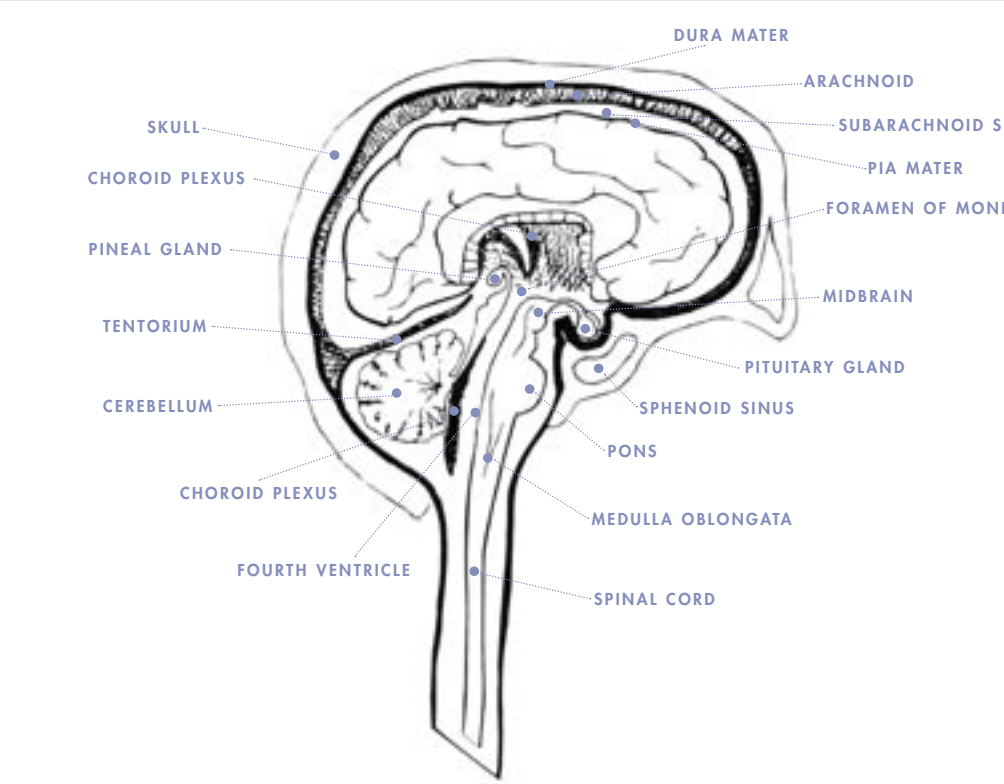

Chapter 2

Brain Tumor Basics

The adult body normally forms new cells only when they are needed to replace old or damaged ones. Infants and children form new cells to complete their development in addition to those needed for repair. A tumor develops if normal or abnormal cells multiply when they are not needed.

A brain tumor is a mass of unnecessary cells growing in the brain. There are two basic kinds of brain tumors — primary brain tumors and metastatic brain tumors. Primary brain tumors start, and tend to stay, in the brain. Metastatic brain tumors begin as cancer elsewhere in the body and spreads to the brain.

When doctors describe brain tumors, they often use the words "benign" or "malignant." Those descriptions refer to the degree of malignancy or aggressiveness of a brain tumor. It is not always easy to classify a brain tumor as "benign" or "malignant" as many factors other than the pathological features contribute to the outcome.

Primary Brain Tumors

A tumor that starts in the brain is a primary brain tumor. Glioblastoma multiforme, astrocytoma, medulloblastoma, and ependymoma are examples of primary brain tumors. Primary brain tumors can be grouped into benign tumors and malignant tumors.

BENIGN BRAIN TUMORS

A benign brain tumor consists of very slow growing cells, usually has distinct borders, and rarely spreads. When viewed under a microscope, the cells have an almost normal appearance. Surgery alone might be an effective treatment for this type of tumor. A brain tumor composed of benign cells, but located in a vital area, can be considered to be life-threatening — although the tumor and its cells would not be classified as malignant.

MALIGNANT BRAIN TUMORS

A malignant brain tumor is usually rapid growing, invasive, and life-threatening. Malignant brain tumors are often called brain cancer. However, since primary brain tumors rarely spread outside the brain and spinal cord, they do not exactly fit the general definition of cancer.

Cancer is a disease defined by:

- unregulated growth of abnormal cells
- abnormal cells that grow into/around parts of the body and interfere with their normal functioning
- spread to distant organs in the body

Brain tumors can be called malignant if they:

- have the characteristics of cancer cells or
- are located in a critical part of the brain or
- are causing life-threatening damage

Malignant brain tumors that are cancerous can spread within the brain and spine. They rarely spread to other parts of the body. They lack distinct borders due to their tendency to send "roots" into nearby normal tissue. They can also shed cells that travel to distant parts of the brain and spine by way of the cerebrospinal fluid. Some malignant tumors, however, do remain localized to a region of the brain or spinal cord.

BENIGN TUMORS	MALIGNANT TUMORS
• slow growing	• usually rapidly growing
• distinct borders	• invasive
• rarely spread	• life-threatening

Metastatic Brain Tumors

Cancer cells that begin growing elsewhere in the body and then travel to the brain form metastatic brain tumors. For example, cancers of the lung, breast, colon and skin (melanoma) frequently spread to the brain via the bloodstream or a magnetic-like attraction to other organs of the body.

All metastatic brain tumors are, by definition, malignant.

ARTERIAL BLOOD FLOW

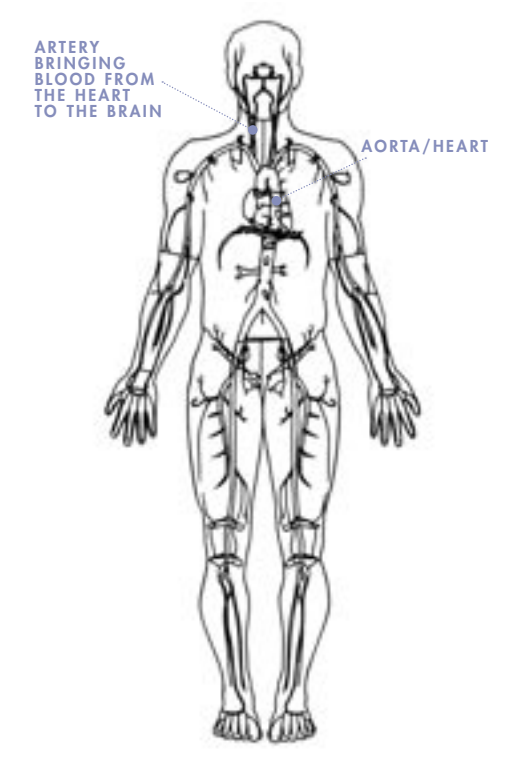

Tumor Names

Tumors are diagnosed and then named based on a classification system. Most medical centers now use the World Health Organization (WHO) classification system for this purpose.

Tumor Grading

Tumors are graded to facilitate communication, to plan treatment, and to predict outcome. The grade of a tumor indicates its degree of malignancy.

Grade is assigned based on the tumor's microscopic appearance using some or all of the following criteria:

- similarity to normal cells (atypia)
- rate of growth (mitotic index)
- indications of uncontrolled growth
- dead tumor cells in the center of the tumor (necrosis)
- potential for invasion and/or spread (infiltration) based on whether or not it has a definitive margin (diffuse or focal)
- blood supply (vascularity)

Using the WHO grading system, grade I tumors are the least malignant and are usually associated with long-term survival. The tumors grow slowly, and have an almost normal appearance when viewed through a microscope. Surgery alone might be an effective treatment for this grade of tumor. Pilocytic astrocytoma, craniopharyngioma, and many tumors of neurons — for example, gangliocytoma and ganglioglioma — are examples of grade I tumors.

Grade II tumors are relatively slow growing and have a slightly abnormal microscopic appearance. Some can spread into nearby normal tissue and recur. Sometimes these tumors recur as a higher grade.

Grade III tumors are, by definition, malignant although there is not always a sharp distinction between a grade II and a grade III tumor. The cells of a grade III tumor are actively reproducing abnormal cells which grow into nearby normal brain tissue. These tumors tend to recur, often as a higher grade.

The most malignant tumors are given a grade of IV. They reproduce rapidly, can have a bizarre appearance when viewed under the microscope, and easily grow into surrounding normal brain tissue. These tumors form new blood vessels so they can maintain their rapid growth. They also have areas of dead cells in their center. The glioblastoma multiforme is the most common example of a grade IV tumor.

WHO (WORLD HEALTH ORGANIZATION) GRADING SYSTEM

GRADE I TUMOR

- slow growing cells
- almost normal appearance under a microscope
- least malignant
- usually associated with long-term survival

GRADE II TUMOR

- relatively slow growing cells
- slightly abnormal appearance under a microscope
- can invade adjacent normal tissue
- can recur as a higher grade tumor

GRADE III TUMOR

- actively reproducing abnormal cells
- abnormal appearance under a microscope
- infiltrate adjacent normal brain tissue
- tumor tends to recur, often at higher grade

GRADE IV TUMOR

- abnormal cells which reproduce rapidly
- very abnormal appearance under a microscope
- form new blood vessels to maintain rapid growth
- areas of dead cells in center

Tumors often contain several grades of cells. The highest or most malignant grade of cell determines the grade, even if most of the tumor is a lower grade.

Some tumors undergo change. A benign growth might become malignant. In some tumors, a lower-grade tumor might recur as a higher-grade tumor. Your doctor can tell you if your tumor might have this potential.

Change of Diagnosis

Although it may initially seem alarming, your diagnosis and the name of your tumor might be changed. There are several factors that might cause the change in diagnosis:

- Be aware that classification of brain tumors by the pathologist is a subjective procedure that is not always straightforward. Different pathologists might disagree about the classification, and grade, of the same tumor.
- Tumors do not always remain static. They can undergo transformation, usually to a higher grade. If that occurs, the name and grade of the tumor might change. A grade III anaplastic/malignant astrocytoma could become a glioblastoma (also called a grade IV astrocytoma).
- Inspecting only a small sample of the tumor, such as that obtained by a needle biopsy, might not be representative of the whole tumor.
- As scientists learn more about the biology of brain tumors, they are becoming aware of new differences and new similarities in tumors. Sometimes this means re-naming or re-grouping tumors.

All grading systems have inherent difficulties — they are not precise.

- Criteria used to assign grades are subject to interpretation by each pathologist.
- Tumors are not uniform, and the sample examined might not be representative of the entire tumor.

Tumor Staging

Staging determines if a tumor has spread beyond the site of its origin. In cancers such as breast, colon, or prostate this is primarily accomplished by a pathologist's examination of nearby tissue such as lymph nodes. In those cancers, staging is a basic part of the diagnostic work-up.

Staging for central nervous system (CNS) tumors is usually inferred from CT scan or MRI images, or by examining the cerebrospinal fluid. Scans taken after surgery are used to determine if there is remaining tumor. CNS tumors that are especially prone to spread are studied with both scan images and laboratory tests. For example, patients with medulloblastoma will often have their cerebrospinal fluid examined for the presence of tumor cells. Those patients will also have scans of their spinal cord because of that tumor's tendency to spread there.
Staging information often influences treatment recommendations and prognosis.

Prognosis

Prognosis means prediction. It is an educated guess about the future course of a disease in a specific individual.

Prognosis is based on the type of tumor, its grade, location, and spread (if any), the age of the patient, how long the patient had symptoms before the tumor was diagnosed, how much the tumor has affected the patient's ability to function, and the extent of surgery if surgery was performed.

The type of therapy is also instrumental. Certain tumors, although malignant, can be cured by radiation therapy or chemotherapy. Others, by virtue of their location, may ultimately be lethal in spite of their "benign" appearance under the microscope.

Additional information about tumor prognosis is also available in our Focusing on Tumors series of publications.

About "Lesions"

"Lesion" is a general term which refers to any change in tissue. Tumor, inflammation, blood, infection, scar tissue, or necrosis (dead cells) are all examples of lesions that may be found in the brain. Determining the nature of the lesion is the work of the pathologist.

If your doctor tells you a "lesion" was seen on your scan, the next step is to ask your doctor what *type* of lesion s/he believes this to be. Treatment will be determined based on the type of lesion.

Chapter 3

Facts & Statistics

Brain tumors do not discriminate. Primary brain tumors occur in people of all ages, but they are statistically more frequent in two age groups — children under the age of 15, and older adults. Metastatic brain tumors are much more common in adults.

Spinal cord tumors are less common than brain tumors. Although they affect people of all ages, they occur most frequently in young and middle-aged adults.

The facts and statistics here include brain and spinal cord tumors (central nervous system tumors). We continually update these statistics, as they become available, at our web site: www.abta.org.

Incidence Statistics

An estimated 40,900 new cases of primary brain tumors are expected to be diagnosed in 2004. This is based on an incidence rate of 14 per 100,000 persons[1] and a projected 2004 U.S. population of 285,266,000 *(www.census.gov)*.

Incidence is the number of people newly diagnosed in one year. **Rate** is the measure of the amount of a disease in a specific population. It is calculated by counting the number of people with the disease and dividing by the total population at risk.

Why is there a wide variation in the reported incidence of primary brain tumors? Sources that quote the incidence of brain tumors at 18,000+ or 19,000+ people diagnosed per year are based on data counting only malignant brain tumors. The incidence statistics stated above (40,900 persons diagnosed per year) include those with all primary brain tumors, both malignant and benign, and are based on the year 2004 population.

In the United States, approximately 3,140 children younger than age 20 are diagnosed annually with primary brain tumors.

Brain tumors are the most common of the solid tumors in children, and the second most frequent malignancy of childhood.[2]

Although statistics for brain metastases are not readily available, it is estimated that over 100,000 cancer patients per year will have symptoms due to metastatic brain tumors and up to 80,000 per year will have a metastatic tumor in the spinal cord.[3] *Metastatic brain tumors* begin as a cancer elsewhere in the body and spread, or metastasize, to the brain. *Primary brain tumors* are tumors that begin in the brain and tend to stay in the brain.

Regarding Incidence Trends

The incidence of malignant brain tumors appears to be level in nearly every age group except for those 85 years and older for whom use of scanning techniques is still increasing.[4] Previous reports of an increase in primary brain tumors may be due to improvements in diagnosis and changes in the diagnosis and treatment of the elderly.[4]

Prevalence Statistics

NOTE — these prevalence statistics refer to primary brain tumors only. *Prevalence* is the total number of people now living following the diagnosis of a brain tumor.

It is estimated that, during the year 2000, approximately 359,000 people in the United States were living after the diagnosis of a primary brain tumor.[5] This is the prevalence for brain tumors, as opposed to the incidence which reflects the number of people newly diagnosed in a given time period. Note: year 2000 prevalence statistics are the most recent available.

For every 100,000 people in the United States, approximately 131 are living following the diagnosis of a brain tumor. This represents a prevalence rate of 130.8 per 100,000 persons.[5]

Of the brain tumor survivors, about 75% were diagnosed with benign tumors. About 23% were diagnosed with malignant tumors, and 2% of the tumors were of uncertain behavior.[5]

BRAIN TUMOR TYPES FOR PEOPLE LIVING WITH A BRAIN TUMOR

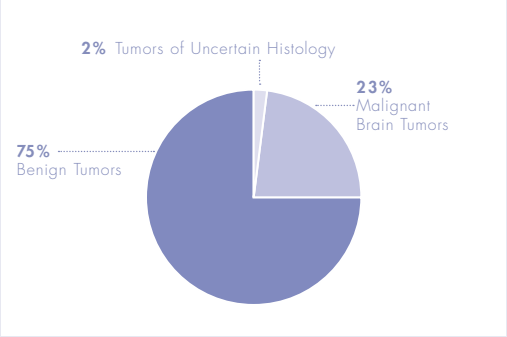

The prevalence rate for primary malignant tumor survivors is estimated to be 29.5 per 100,000. The prevalence rate for primary benign tumor survivors is estimated to be 97.5 per 100,000 persons.[5]

Pediatric Statistics

An estimated 3,140 children less than 20 years of age will be diagnosed with a primary benign or malignant brain tumor during the year 2004.

The incidence rate of primary brain tumors in children is 3.9 cases per 100,000 children. The rate is slightly higher in males (4.1 per 100,000) than females (3.8 per 100,000).[1]

Brain tumors are the second most frequent malignancy of childhood and the most common of the solid tumors.[2]

Brain tumors are the second leading cause of cancer-related deaths in children under the age of 20. Leukemia remains the first.[2,6]

Trends in incidence of primary malignant brain tumors for children in the United States using Surveillance, Epidemiology, and End Results (SEER) Program data and a sophisticated statistical technique were recently evaluated.[7] *SEER* is a program of the National Cancer Institute. It collects and analyzes information on cancer incidence, mortality, and survival in the US. SEER data does not include benign brain tumors. The incidence of brain malignancies did not increase steadily from 1973 to 1994 as previously reported, but rather "jumped" to a steady, higher rate after 1984-85. The timing of the "jump" coincided with the wider availability of magnetic resonance imaging (MRI) in the United States. This finding, combined with the absence of any "jump" in corresponding mortality for the same period, appears due to improved diagnosis and reporting during the 1980s.[7]

Age- and Gender-Specific Statistics

The incidence rate of primary brain tumors is 14.2 per 100,000 for males and 13.9 per 100,000 for females.[1] Rates are age-adjusted to the year 2000 US standard population.

Brain tumors are the:

- leading cause of cancer-related deaths in males ages 20-39[6]
- fifth leading cause of cancer-related deaths in women ages 20-39[6]

Within the following age groups, the most common primary brain tumors are:

- in ages 0-4, embryonal/primitive neuroectodermal tumors/medulloblastomas
- in ages 5-9, pilocytic astrocytomas
- in ages 10-14, pilocytic astrocytomas
- in ages 15-19, pilocytic astrocytomas
- in ages 20-34, pituitary tumors
- in ages 35-44, meningiomas
- in ages 45-54, meningiomas
- in ages 55-64, glioblastomas
- in ages 65-74, glioblastomas
- in ages 75-84, meningiomas
- in ages 85 and older, meningiomas[1]

COMMON PRIMARY BRAIN TUMORS, BY AGE



TYPES OF PRIMARY BRAIN TUMORS

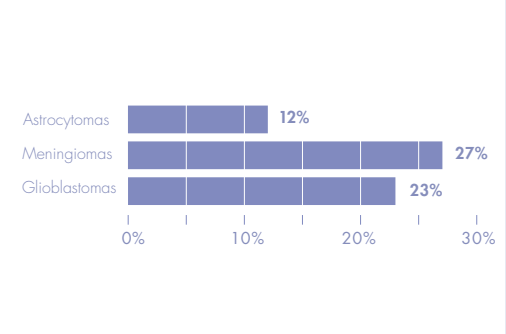

Tumor-Specific Statistics

Meningiomas represent 27% of all primary brain tumors, making meningiomas the most common primary brain tumor.[1]

Glioblastomas represent 23% of all primary brain tumors.[1]

Astrocytomas represent 12% of all primary brain tumors.[1]

Nerve sheath tumors (such as acoustic neuromas, vestibular schwannomas, neurilemmomas) represent 8% of all primary brain tumors.[1]

Pituitary tumors represent 7% of all primary brain tumors.[1]

Lymphomas represent 3% of all primary brain tumors.[1]

Oligodendrogliomas represent 3% of all primary brain tumors.[1]

Medulloblastomas/embryonal/primitive tumors represent 2% of all primary brain tumors.[1]

Metastatic brain tumors are the most common brain tumor, with an annual incidence more than four times greater than that of primary brain tumors.

The cancers that most commonly metastasize to the brain are lung and breast.

Survival Trends

A significant increase in survival rates for those with primary malignant brain tumors has been reported in data obtained from SEER. During 1974–1976, 22% of those diagnosed in the US with a malignant brain tumor survived five years. For those diagnosed from 1992-1998, that survival rate increased to 32%. This represents a significant statistical increase in survival over the past twenty years.[6]

For Whites, the five year survival rates for the time periods referenced above increased from 22% to 32%.[6]

For African-Americans, the five year survival rates for the time periods referenced above increased from 27% to 40%.[6]

For children under the age of fifteen, the five year survival rates for the time periods referenced above increased from 55% to 70%.[6]

NOTE: The term "five year survival" does not mean that the people in this study lived only five years. Five years is a standard "goal" in measuring survival for most diseases. Five year survival statistics do not tell us how many people lived longer. Those statistics require a longer-term follow-up of people diagnosed with that disease, which can be challenging to do in our society.

Sources

[1] CBTRUS (2002-2003). Primary Brain Tumors in the United States Statistical Report 1995-1999. Central Brain Tumor Registry of the United States.

[2] Ries LAG, Smith MA, Gurney JG, Linet M, Tamra T, Young JL, Bunin GR (eds). Cancer Incidence and Survival among Children and Adolescents: United States SEER Program 1975-1995, National Cancer Institute, SEER Program. NIH Pub. No. 99-4649. Bethesda, MD, 1999.

[3] Lenhard Jr. RE, Osteen RT, Gansler T. Clinical Oncology, American Cancer Society, 2001, p. 655.

[4] Legler JM, Ries LAG, Smith MA, Warren JL, et al. "Brain and Other Central Nervous System Cancers: Recent Trends in Incidence and Mortality." Journal of the National Cancer Institute, Vol. 91, No. 16, August 18, 1999, pp. 1382-1390.

[5] Davis FG, Kupelian V, Freels S, McCarthy B, Surawicz T. "Prevalence estimates for primary brain tumors in the United States by behavior and major histology groups." Neuro-Oncology, Vol. 3, No. 3, June, 2001, pp. 152-158.

[6] Jemal A, Thomas A, Murray T, Samuels A, et al. Cancer Statistics, 2003. CA: A Cancer Journal for Clinicians. American Cancer Society. Jan/Feb 2003, Vol. 53, No. 1., pp. 5-26.

[7] Smith MA, Freidlin B, Ries LAG, Simon R. "Trends in reported incidence of primary malignant brain tumors in children in the United States." Journal of the National Cancer Institute, Sept 1998, Vol. 90, No. 17, pp. 1269-1277.

For Additional Information

In 1990, the American Brain Tumor Association conducted a feasibility study to evaluate the status of brain tumor data collection, and to determine the practicality of starting a registry whose purpose would be the collection of statistics for both benign and malignant brain tumors. The results of that study highlighted both the need and feasibility of such a registry. The American Brain Tumor Association then incorporated the Central Brain Tumor Registry of the United States (CBTRUS), and provided organizational and financial support to the new entity.

CBTRUS was incorporated as a not-for-profit organization in 1992 to provide a resource for the gathering and circulating of current information on all primary brain tumors, benign and malignant, for the purposes of:

- describing incidence and survival patterns
- evaluating diagnosis and treatment
- facilitating etiologic (causation) studies
- establishing awareness of the disease
- and, ultimately, for the prevention of all brain tumors

State or regional tumor registries obtain information about brain tumor patients from hospitals in their area. CBTRUS began by collecting information from four registries that were already collecting data on benign and malignant brain tumors. Using their preliminary data, CBTRUS conducted studies to determine diagnostic accuracy and data completeness. They now have the voluntary collaboration of 15 state registries, and encourage other population-based registries that collect data on benign and malignant brain tumors to contact them about their efforts. The data collected is used to define incidence rates of all primary brain tumors, and can be used by researchers to identify geographic clusters of patients.

CBTRUS joined the North American Brain Tumor Coalition in supporting federal legislation (Public Law 107-260) that passed in October 2002 that enables government funded surveillance organizations to collect data on primary benign brain tumors beginning in 2004.

Please visit the web site of the Central Brain Tumor Registry at *www.cbtrus.org*. For more information or additional statistical data on primary brain tumors contact CBTRUS at 3333 West 47th Street, Chicago, Illinois 60632. Phone: 630-655-4786 Web: www.cbtrus.org

Chapter 4

Causes & Risk Factors

No risk factor accounting for the majority of brain tumors has been identified even though many environmental and genetic factors have been, and are, being studied. However, there are many groups across the United States and around the world focused on discovering the causes and/or risk factors for brain tumors.

Brain tumor epidemiologists look for causes and risk factors that would explain why people develop brain tumors. Causes and risk factors can be environmental, such as being exposed to poisonous substances in the home or at work, eating or not eating certain foods, or whether or not we exercise/smoke cigarettes/drink alcohol. They can be genetic, such as being born with a mutation/susceptibility that one inherits from parents. Or, these genetic mutations/susceptibilities may accumulate over time, as one grows older.

Environmental Factors

Many studies have examined a wide spectrum of environmental factors as a cause for brain tumors. Of the long list of factors studied, only exposure to ionizing radiation has consistently been shown to put one at *increased* risk for developing a brain tumor. Some studies have shown a history of allergies as an adult, a mother eating fruits and vegetables during pregnancy, eating fruits and vegetables as a child, and having chicken pox as a child puts one at a *decreased* risk of development of brain tumors.

However, environmental exposures can be difficult to accurately measure leading to inconsistent results across studies. Therefore, inconsistent results have been found, in both adults and children, for a long list of environmental factors. These factors include: vinyl chloride exposure, working in synthetic rubber manufacturing or petroleum refining/production, history of head trauma, epilepsy, seizures or convulsions, cured food consumption (nitrites), viruses and common infections, cigarette smoking, alcohol consumption, cell phone use (in the United States and in Europe), residential power line exposure, exposure to air pollution, smoking when pregnant, second hand smoke exposure, agricultural worker exposures, industrial formaldehyde exposure and use of common drugs (for example, birth control pills, sleeping pills, headache medication, over-the-counter pain medication, antihistamines). More studies need to be performed before we can say whether or not these are true risk factors for developing a brain tumor.

Genetic Factors

Anything that refers to our genes can be called "genetic". However, only 5–10% of all cancer is actually inherited from one generation to another in a family (i.e. "heredity"). Hence, there are very few families where multiple people in that family would have a brain tumor. There are a few rare, hereditary genetic syndromes that involve brain tumors. In those syndromes, a mutation in a specific gene is passed from grandparent, to parent, to child. These syndromes, along with the inherited gene, are: NF1 (NF1 gene), NF2 (NF2 gene), Turcots (APC gene), Gorlins (PTCH gene), tuberous sclerosis (TSC1 and TSC2 genes) and Li-Fraumeni syndrome (TP53 gene).

The vast majority of genetic risk factors are not inherited at birth but actually accumulate over time as we age. Genes are the operating instructions for the entire body. While most of our genes go about their jobs as expected, a small number may become inactive or begin functioning abnormally. The end result of an abnormal gene can be as simple as two different colored eyes or as complex as the onset of a disease. There are many different types of genes thought to be working incorrectly in brain tumors:

- *Tumor suppressor genes* make proteins that stop tumor growth in normal cells. The most well-defined tumor suppressor gene is TP53, which is believed to play a role in causing a low-grade brain tumor to develop into a high-grade brain tumor.
- *Oncogenes* make proteins that cause cells to grow in an out-of-control manner.
- *Growth factors* play a role in making sure that cells grow normally. EGFR is a growth factor that has been well studied in brain tumors and has been shown to be in very high quantities in high-grade brain tumors, causing these tumors to grow abnormally fast.
- *Cyclin-dependent kinase inhibitors* play a role in making sure that the cell goes through its growth cycle normally.

- *DNA repair genes* make proteins that control accurate repair of damaged DNA. ERCC1 is a DNA repair gene that has been shown to be associated with oligodendrogliomas but not with GBMs.
- *Carcinogen metabolizing genes* make proteins that break down toxic chemicals in the body that could cause damage to one's DNA, like the chemicals in cigarette smoke and/or alcohol.
- *Immune response genes* make proteins that control how one's immune system responds to viruses and infections.

However, studies of any specific gene are complicated by the fact that there are many potential genes in the human genome to consider. One must also consider that many of these genes interact with one another, and they may interact with environmental factors as well.

Tumors can also have loss or gain of certain pieces of *chromosomes*. Each normal cell in any human body has 23 pairs of chromosomes, 22 autosomal pairs and one sex pair (two X chromosomes make a female and one X chromosome and one Y chromosome make a male). The most common chromosomal changes in brain tumors occur on chromosomes 1, 10, 13, 17, 19 and 22. Changes on chromosomes 1 and 19 are most frequently found in oligodendrogliomas and changes on chromosome 22 are most frequently found in meningiomas.

Medline Searches

To learn more about potential causes of brain tumors, you can perform a medical literature search on the Internet using Medline, a medical literature search program offered by the National Library of Medicine. Medline can be found at *www.nlm.nih.gov*. This computer program searches medical journals (the journals scientists read) for articles containing the keywords and limits you specify. It has an easy "fill-in-the-blank" format and online help options.

We can also e-mail step-by-step instructions for performing your own Medline Search. Call us at 800-886-2282 or send a message to *info@abta.org*.

Questions About Heredity

"My family member has a brain tumor. Should I be tested too?" Concerns about heredity and brain tumors are common, and if you have concerns about your family history, we suggest the following:

- Begin by sharing your family's medical history with your primary physician. He or she will want to know the type of brain tumor and your relation to the person with the tumor. Although routine screening for brain tumors is not available as it is for breast or cervical cancer, unusual symptoms — such as headaches or short term memory loss — can be investigated with your family history in mind.
- If you have multiple family members diagnosed with brain tumors, or have concerns about starting a family, consider a consultation with a genetic counselor. He or she can access the latest genetic information related to the specific tumor type in your family and advise you accordingly. The Cancer Information Service at 800-422-6237 can help you find a genetic counselor.

Chapter 5

Diagnosis & Follow-Up

Initially, the question is whether or not you have a brain tumor. If you do, the next step is to determine the type of tumor. In this chapter we outline the various tests your health-care team may order to make that diagnosis.

Some of the same tests used to first diagnose your tumor are also used to monitor your progress — to see if the tumor disappeared, is shrinking, remains the same or has changed. Follow-up care for a brain tumor might extend for years or even a lifetime, not unlike many other medical conditions.

Understanding the tests — what they are, how they work, and what they can or cannot show — can help you feel more comfortable and in control. If at any time you have questions about the tests ordered for you, feel free to ask. Your nurses, and the professionals giving these tests, can provide answers, fact sheets, instructional materials, and the reassurance you need to make you feel at ease with these procedures.

Making a Diagnosis

Your doctor begins to make a diagnosis by taking your medical history. You are asked to describe your symptoms, how long you have had them, when they occur, if they seem to be brought on by something in particular, the order of their appearance, and if they seem to be getting worse. Following the question and answer phase of the process, your doctor will perform a basic neurological examination in the office.

Neurological Exam

A basic neurological examination includes the following:

- tests for eye movement by following a moving finger; pupil reaction, and eye reflex using a pen light
- vision tests and examination of the optic nerve
- hearing tests using a ticking watch or tuning fork
- reflex tests using a rubber hammer
- balance and coordination tests — heel-to-toe walking, heel-to-shin movements; balance with feet together and eyes closed; rapid alternating movements such as touching the finger to the nose with eyes closed
- sense of touch tests using a sharp object and cotton ball or paint brush
- sense of smell tests with various odors
- facial muscle tests — smiling, grimacing
- tongue movement, gag reflex tests
- head movement tests
- mental status tests — i.e. stating the current time and date, naming the current President
- abstract thinking tests — i.e. defining the meaning of "a stitch in time saves nine"
- memory tests — i.e. repeating a list of objects, describing the food you ate at yesterday's breakfast, what occurred last Thanksgiving

If the results of your neurological examination lead the doctor to suspect you have a brain tumor, a scan will be ordered, or you might be referred to a neurological specialist for additional testing. Those tests might include the following scans, xrays, or laboratory tests.

Scans

Scans take the place of conventional x-rays, which do not show tumors located behind the bones of the skull or spine. Different types of imaging devices are used to perform scans. The most common scans for diagnosis and follow-up are Magnetic Resonance Imaging (MRI) and Computerized Tomography (CT).

Both MRIs and CTs use computer graphics to create an image of the brain. An injection of a special contrast material (dye) to make abnormal tissue more obvious is usually given during the scan. The contrast materials concentrate in diseased tissues in greater quantity than in healthy tissues. That concentration is due to the leakiness of blood vessels in and around brain tumors. Contrast materials highlight abnormalities such as tumors.

Small tumors, tumors next to bone, brain stem tumors, low grade and metastatic tumors might be imaged better by MRI than CT. CT is more effective at showing calcification and bony erosion. Your doctor determines which scan/s to use.

CT SCAN

This scan combines an x-ray device with a computer. For some types of tumors, CT images are obtained both with and without contrast enhancement to provide important additional information.

If contrast is used, it is usually injected after a few pictures are taken. The patient lies on a table that slides into a doughnut-shaped opening. The CT scanner circles the head so x-rays penetrate the brain from many directions. Absorption of the x-rays varies with the type of tissue penetrated. Thousands of thin cross-section readings are fed into the computer, which transforms the information into a picture.

MRI SCAN

The MRI is a tunnel-shaped piece of equipment. Some pictures are taken prior to contrast injection. If contrast is to be used, it is injected prior to the completion of the scan. The patient lies on a table that slides into the tunnel. Inside the scanner, a magnetic field surrounds the head. A radio frequency pulse is introduced to the area. No x-rays are used. The magnetic field causes atoms in the brain to change direction. The radio frequency pulse causes another change of direction. When the pulse stops, the atoms relax and return to their original position. During relaxation, the atoms give off energy in differing amounts and at different intervals of time. Antennas pick up these signals and feed them into a computer, which assembles a picture. Because different atoms have their own characteristic radio signals, the computer can distinguish between healthy and diseased tissue.

Patients with some cardiac monitors, pacemakers, or some types of surgical clips cannot undergo MRI scanning because of the magnetic fields. For those who are claustrophobic, sedation or "open" MRI scanners may be an option.

OTHER CT OR MRI BASED SCANS

Computer technology advances have made possible the development of new methods for using existing scanning equipment. These new methods provide advanced tools for diagnosis.

Most of these new tools measure the rate of blood flow into the brain. A contrast dye is given to the patient by intravenous (IV) infusion. The scanner begins taking pictures as soon as the dye is given. Using computerized timing, a succession of rapid pictures can be imaged, tracing the path of blood flow into the brain and to the brain tumor. These techniques are also used to scan spinal cord tumors.

These new methods are collectively called hemodynamic imaging. The information gathered can be converted into images or graphed into charts. Several different types of scanning equipment are used to produce these images: CT, MRI, PET, and SPECT.

Dynamic CT and Dynamic MRI
The CT or MRI is combined with the ability to measure the uptake of the contrast dye from the time it begins to flow from the IV. Dynamic scans are especially useful in showing the growth of new blood vessels around a tumor.

MRI SCAN

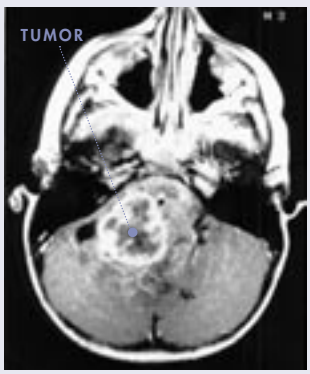

This MRI scan shows an ependymoma.

Scan courtesy of Dr. Regina Jakacki

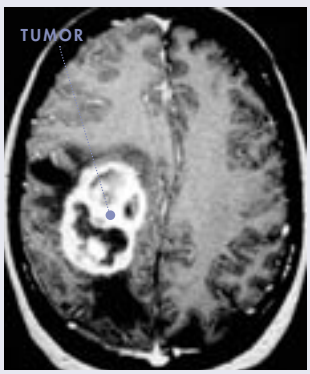

MRI scan of a glioblastoma multiforme.

Scan courtesy of Dr. Jeffrey Bruce

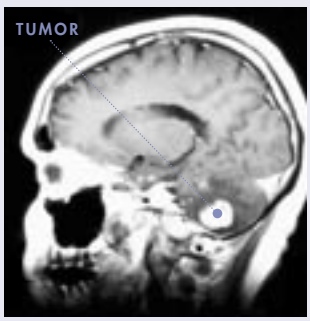

MRI scan of a single breast metastasis in the cerebellum.

Scan courtesy of Dr. Deborah Heros

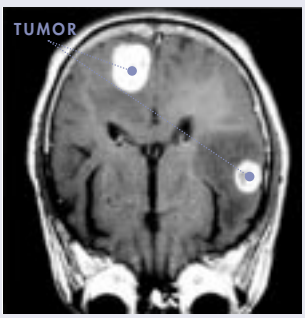

MRI scan of multiple brain mestastases.

Scan courtesy of Dr. Raymand Sawaya

Functional MRI
(also called Echoplanar, "Real Time" or Fast MRI)
This technique produces MRI images in a faster sequence than traditional MRIs. The increased speed permits the tumor's use of oxygen to be depicted. Functional MRI may be useful prior to or during surgery to show the specific areas of the brain that control speech, movement, and memory so they can be avoided.

Flow Sensitive MRI (FS MRI)
This type of scan combines functional MRI with images of cerebrospinal fluid (CSF) flow. FS MRI can be used to show the flow of CSF through the ventricles and spinal cord. It can be useful in planning for the surgical removal of a skull base tumor, spinal cord tumor, or a tumor causing hydrocephalus.

ANGIOGRAPHY AND MRI ANGIOGRAPHY (MRA)

Angiography is used to outline the presence and position of blood vessels in the brain. After injection of a contrast material into a deep artery, x-rays follow its flow through the blood vessels of the brain. MRI angiography, which is less invasive, uses a rapid succession of MRI scans to follow the blood flow, and can be done with or without the injection of contrast dye.

The role of angiography for brain tumors is usually limited to planning the surgical removal of a tumor suspected of having a large blood supply, or tumors growing into an area of the brain with an abundance of blood vessels. At times, angiography can be used as a means of embolizing or closing-off large blood vessels which feed the tumor, making surgery easier.

MRS (MAGNETIC RESONANCE SPECTROSCOPY)

MRS produces images depicting function rather than shape. The equipment requires a special, highly complex facility.

Capable of measuring some byproducts of living tissue (called metabolites), this non-invasive scanning technique can depict patterns of activity that may be useful in diagnosing specific tumors. MRS may be useful with low grade gliomas, tumors with a large amount of surrounding edema and in differentiating between tumor recurrence and radiation necrosis. This technique may also be valuable in suggesting the degree of malignancy. MRS and PET are complementary tools for metabolic imaging.

PET (POSITRON EMISSION TOMOGRAPHY, FDG-PET)

PET is not routinely used for diagnosis but it can complement scanning information by suggesting tumor grade. It can also be used to try to distinguish between recurrent tumor versus cells killed by radiation (necrosis) versus scar tissue.

In a PET scan, a low-dose of radioactive sugar (called FDG) is injected into the patient. The PET scanner rotates around the patient's head, detecting the amount of radioactive sugar taken up by various parts of the brain. A growing tumor consumes sugar at a high rate; radiation necrosis or scar tissue consumes almost no sugar.

Measurements of brain activity (determined by concentrations of the sugar) feed into a computer, which produces a color-coded moving picture or a black and white image of the brain as it converts sugar into energy. The use of PET had been limited because it requires complex equipment. There also can be false negatives and positives. An increasing number of facilities now offer or can arrange PET scanning. Truck-mounted mobil PET and PET/CT scanners are also bringing this technology into the community.

SPECT (SINGLE PHOTON EMISSION COMPUTERIZED TOMOGRAPHY)

SPECT is not routinely used in the initial diagnosis of a brain tumor, but might complement information obtained from other scans.

A SPECT scan is similar to PET. Radioactive tagged materials taken up by the brain are used. A special camera measures the rate of emission of the material as it moves through the brain. Images are generated from that information. After MRI or CT, this test might be helpful in distinguishing between low-grade and high-grade tumors, or between recurrent tumor and necrosis.

MEG (MAGNETOENCEPHALOGRAPHY)

The MEG scan measures the magnetic fields created by nerve cells as they produce the small electrical currents used for neurotransmission. No physical contact is required to record the signals.

The device looks like an old-fashioned hair dryer. When the patient moves, a computer-generated image shows which brain area is responsible for directing the motion.

MEG is used in combination with information from other types of scans to determine the function of specific areas of the brain. However, MEG scanning is available at a very limited number of facilities.

X-Rays

Plain skull x-rays are usually not necessary for diagnosis except to help determine if calcification or bony erosion is present. Slow growing tumors can cause calcification; increased intracranial pressure might cause erosion. X-rays might be used to determine the condition of the skull adjacent to meningeal and skull base tumors.

A radiologist interprets the computer images produced by scans and x-rays. The pictures help establish a tentative diagnosis and might suggest the type of tumor — but they are not definitive. Only examination of a sample of tumor tissue under a microscope provides an exact diagnosis.

Laboratory Tests

LUMBAR PUNCTURE (SPINAL TAP)

Lumbar puncture is used to obtain a sample of cerebrospinal fluid (CSF). This procedure is usually avoided if there is any indication of increased intracranial pressure because of the risk of the brain's bulging through an opening in a membrane, muscle, or bone (herniation).

The sample of CSF is examined in a laboratory to determine if tumor cells, infection, protein, or blood is present. This information is particularly helpful in diagnosing primary CNS lymphoma, a pineal region or meningeal tumor. After surgery, the presence of tumor cells in the CSF indicates tumor spread. That information is used for tumor staging and helps the doctor determine appropriate treatment choices.

The CSF is also examined for the presence of known tumor markers, substances which indicate the presence of a tumor.

Unfortunately, most primary brain tumors have no tumor markers. At this time, only some germ cell tumors are known to produce those substances. Known germ cell tumor markers are:

AFP alpha-fetoprotein

HCG human chorionic gonadotropin

PLAP placental alkaline phosphatase

CEA (carcinoembryonic antigen) is a marker for a tumor of the arachnoid and/or pia mater membranes of the meninges (a leptomeningeal tumor). These are usually metastatic tumors.

If they are present, tumor markers are helpful in the diagnosis and follow-up evaluation of germ cell and metastatic brain tumors only.

MYELOGRAM

Lumbar puncture is used to inject a special dye before a myelogram. The patient is then tilted to allow the dye to mix with the spinal fluid. This test is used primarily to diagnose a spinal tumor and obtain pre-operative information for spinal tumor surgery.

Spinal MRI has replaced myelography for many conditions.

EVOKED-POTENTIALS

Evoked-potential testing uses small electrodes to measure the electrical activity of a nerve. This test is particularly useful in detecting a vestibular schwannoma (acoustic neuroma).

Evoked-potentials can also be used to monitor neurological function during the surgical removal of a tumor.

AUDIOMETRY

This hearing test is useful in the diagnosis of a cerebellopontine angle tumor such as the vestibular schwannoma (acoustic neuroma).

ENDOCRINE EVALUATION

Measurements of hormone levels in samples of blood and urine are used, along with scans, to diagnose a pituitary or hypothalamic tumor.

Hormone	Responsible for...	Normal Blood Levels in Adults
ACTH adrenocorticotropic hormone	Controls the production of cortisol — a natural steroid needed to control blood pressure, sugar and salt levels	9 to 52 pg/ml
GH growth hormone	Controls bone growth; height; body proportion in the extremities and jaw	0 to 3 ng/ml
PRL prolactin	Controls milk production in women, impacts sex drive and sperm counts in men	Males and non-pregnant women: 0 to 20 ng/ml In pregnancy: 10 to 300 ng/ml
TSH thyroid stimulating hormone	Controls thyroid functions such as metabolism, heart rate and appetite	0.2 to 4.7 mcU/ml

PERIMETRY

This technique measures the size of visual fields. The information obtained might be useful in diagnosing a tumor in the area of the optic chiasm, such as a pituitary tumor.

Biopsy

A biopsy is a surgical procedure in which a small amount of tumor tissue is removed. The neurosurgeon submits the tumor tissue to a pathologist for study and analysis. Only then is a tissue diagnosis possible.

A biopsy can be performed as part of the surgery to remove the tumor, or as a separate diagnostic procedure.

For areas considered to be inoperable, the surgeon is often able to perform a needle biopsy through a small hole drilled into the skull called a burr hole. A narrow, hollow needle is inserted through the burr hole. Tumor tissue is removed from the core of the needle.

Stereotaxic biopsy is a computer directed needle biopsy. The computer, using information from a CT or MRI scan, provides precise information about a tumor's location and its position relative to the many structures in the brain.

Stereotactically-guided equipment might be moved into the burr hole to remove a sample of the tumor. This is called a closed biopsy.

When a biopsy is not performed, diagnosis relies solely on the interpretation of other test results.

About Follow-Up Testing

At intervals during and after treatment, your doctor will probably order some of the same tests you took when your tumor was first diagnosed.

These tests measure the effectiveness of the treatment and monitor for possible recurrence. Other tests help evaluate your medication.

Your doctor will tell you when your next scans or tests should be done. If you don't have this information, call your doctor's office and ask. Follow-up is as important as treatment.

Chapter 6

Types of Brain and Spinal Cord Tumors

This chapter contains, in alphabetical order, information about the more common brain and spinal cord tumors, their typical symptoms and locations, and how they might be treated. Please remember that your tumor is unique and might not conform to the "average" characteristics described.

The tumor names we use are based on the WHO (World Health Organization) brain tumor classification system.

In addition to the tumor and treatment information in this chapter, we also offer two other resources — our *Focusing on Tumors* and *Focusing on Treatment* series of publications. The *Focusing on Tumors* booklets contain detailed information about the most common types of brain tumors: meningioma, glioblastoma and malignant astrocytoma, oligodendroglioma and oglioastrocytoma, metastatic brain tumors, pituitary tumors, medulloblastoma, and ependymoma. The *Focusing on Treatment* booklets explain various types of surgery, radiation therapy, sterotactic radiosurgery, and chemotherapy. Visit our website at www.abta.org to access those resources, or call us at 800-886-2282.

Acoustic Neuroma

Also called Neurilemmoma, Vestibular Schwannoma or Neurinoma

The acoustic neuroma is a benign tumor of the nerve of hearing (the 8th cranial nerve). It is located in the angle between the cerebellum and the pons, in the posterior fossa (the back of the skull). This tumor usually grows very slowly.

CROSS SECTION OF THE EAR

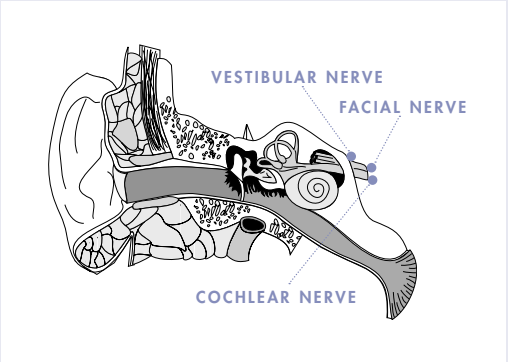

Acoustic neuromas typically occur in adults, particularly in their middle years. Females are twice as likely to have this tumor as males. Acoustic neuromas account for fewer than 7.5% of all primary brain tumors.

Common symptoms are one-sided hearing loss and buzzing or ringing in the ear. Dizziness may also occur, but is less common. If the tumor also affects the facial nerve (the 7th cranial nerve) located next to the 8th nerve, facial paralysis can occur. Other symptoms include difficulty in swallowing, impaired eye movement, taste disturbances, and unsteadiness.

Total removal using microsurgical techniques is often possible. Stereotactic radiosurgery might be used as an alternate to surgery for some patients.

Tumors on both sides (bilateral) are rare, and tend to be familial. They are almost always associated with *neurofibromatosis 2*, a hereditary condition. The malignant form of this tumor, *malignant peripheral nerve sheath tumor* (MPNST), is extremely rare.

For more information on acoustic neuromas, contact:

Acoustic Neuoma Association
600 Peachtree Parkway, Suite 108
Cummings, Georgia 30041

Phone: 770-205-8211
E-mail: ANAUSA@aol.com
Website: www.ANAUSA.org

Astrocytoma

Astrocytomas are tumors that arise from astrocytes — cells that make up the "glue-like" or supportive tissue of the brain. The cells are named for their star-like shape. These tumors are "graded" by the pathologist to indicate how normal, or how abnormal, the cells of the tumor look. Grade I astrocytomas have slightly unusual looking cells; the cells of a grade IV astrocytoma are very abnormal in appearance. In this section we'll describe the various grades of these tumors. The list begins with grade I tumors and progresses through grade IV astrocytomas.

Sometimes, terms describing the location or the appearance of an astrocytoma may be attached to its name. For example, a butterfly glioma is a high grade astrocytoma that has spread through both sides of the brain, causing a "butterfly" appearance on scans. A cerebellar astrocytoma is an astrocytoma found in the cerebellum of the brain.

ASTROCYTE

Astrocytes are the cells that make up the "glue-like" or supportive tissue of the brain.

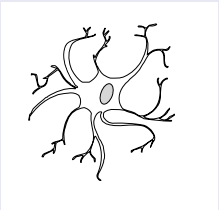

CEREBELLAR ASTROCYTOMA

"Cerebellar astrocytomas" are astrocytomas found in the cerebellum — the lower, back part of the brain which controls balance. More than 80% of cerebellar astrocytomas are grade I, localized, cystic (fluid-filled) tumors although higher grades of tumor do occur. Malignant cerebellar astrocytomas and spread

THE CEREBELLUM

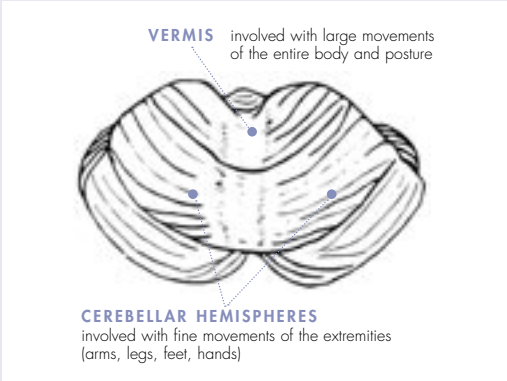

of this type of tumor are rare. The cerebellar location is more common in children than adults and is usually very accessible to the neurosurgeon.

Surgery is the primary treatment and if "total" removal is possible — meaning that all tumor visible to the surgeon's eye is able to be removed — additional therapy might not be needed. In adults and older children, radiation might be recommended for an incompletely removed or a higher-grade tumor. Further treatment might be needed only if the tumor recurs. For children under three, chemotherapy may be used to delay the use of radiation therapy until the brain has further matured.

If the tumor recurs, a second surgery, radiation, or chemotherapy can be considered.

DESMOPLASTIC INFANTILE ASTROCYTOMA (DIA)

DIAs are very rare grade I astrocytomas. These large, cystic tumors are usually diagnosed in infants under the age of two, although in some circumstances they have been seen in older children and young adults. They tend to arise in the supratentorium — the area above the membrane that separates the cerebral hemispheres from the posterior fossa of the brain. It is not uncommon for these tumors to grow quite large and spread through more than one lobe of the brain. Symptoms usually include an increase in the size of the baby's head, hard and bulging fontanelles (the "soft spots" of the infant's skull), and eyes that focus downward. Seizures, hyperactive reflexes, and a palsy of the sixth and seventh nerves may also be seen. Skull xrays may show changes in the bone near the tumor, and a large mass is commonly seen on MRI. Despite the size of these tumors and the young patient age, surgical removal of all visible tumor often results in long term tumor control.

PILOCYTIC ASTROCYTOMA

Also called Juvenile Pilocytic Astrocytoma

These grade I astrocytomas are usually non-infiltrating tumors, meaning they tend to stay in the area in which they started and do not spread into surrounding tissue. They generally form cysts, or may be enclosed within a cyst. Although these are usually slow growing tumors, they can become very large.

Pilocytic astrocytomas are the most common glioma in children. They are generally diagnosed in children and young adults under the age of 20, and are rarely seen in older adults. They are the most benign tumor of the astrocytomas. Many optic gliomas and cerebellar astrocytomas are pilocytic astrocytomas.

Pilocytic astrocytomas are generally considered benign tumors and are often cured by surgery alone. In adults and older children, radiation therapy might follow surgery if the tumor cannot be completely removed, or the residual tumor may be carefully watched. In a "watchful waiting" situation follow-up MRI scans are done at regular intervals to monitor for possible re-growth. If the tumor recurs, re-operation and some form of radiation are options. Some pilocytic tumors, such as most optic gliomas, cannot be safely removed because of their location and initial treatment may involve observation only.

The term "anaplastic" or "malignant" pilocytic astrocytoma is used only when the tumor has developed an extensive blood supply around the tumor, or the tumor contains dead cells called necrosis. These rare tumors require more aggressive treatment than a benign pilocytic astrocytoma

SUBEPENDYMAL GIANT CELL ASTROCYTOMA

Subependymal giant cell astrocytomas are ventricular tumors associated with tuberous sclerosis. *Please see the section on tuberous sclerosis for additional information.*

DIFFUSE ASTROCYTOMA

Also called Astrocytoma, Low Grade or Astrocytoma Grade II (types: Fibrillary, Gemistocytic, Protoplasmic Astrocytoma)

These low grade astrocytomas tend to be infiltrating tumors, capable of growing into surrounding tissue, but tumors which grow relatively slowly.

These astrocytomas are grouped by the appearance and behavior of the cells for which they are named. For example, the nuclei of fibrillary astrocytoma cells are cigar-shaped; this type of astrocytoma tends to contain microcysts and mucous-like fluid. Protoplasmic astrocytoma nuclei are round or oval in shape. These tumors also tend to contain microcysts and mucous-like fluid. Gemistocytic astrocytomas are plump, glassy, angular shaped cells. (Until recently there had been some disagreement as to the grade of the gemistocytic astrocytoma. Some pathologists considered this to be a grade III tumor since the gemistocytic astrocytoma, in particular, tends to recur as an anaplastic astrocytoma. The WHO classification system published in 2000 defines these as grade II tumors.)

Regardless of the cellular appearance of these grade II astrocytomas, surgical removal may be suggested for accessible tumors (tumors that may be removed without causing undue neurological damage). If "total" surgical removal can be achieved, periodic follow-up with MRI or CT scans might be the only additional care required. It is important to realize that "total" removal generally means removal of all of the tumor visible to the neurosurgeon's eye. Microscopic cells, too small to see, can remain behind or may have spread to nearby tissue. Those cells may later begin to re-grow. However, even with incomplete removal these tumors tend to grow very slowly, and it may be several years before symptoms reappear due to tumor re-growth.

In adults and older children, radiation therapy may be suggested in addition to surgery, or radiation may be used to treat a low grade astrocytoma which is unable to be removed. The role of chemotherapy in treating these tumors is under investigation. Further treatment might be recommended only if the tumor recurs. Children younger than three might receive chemotherapy so that radiation can be delayed.

These low grade tumors may recur as a higher grade tumor; thus, periodic follow-up and attention to the return of symptoms is important. Treatment of the recurrent tumor would be based on the tumor's grade at the time of re-growth.

ANAPLASTIC ASTROCYTOMA

Also called Malignant Astrocytoma or Grade III Astrocytoma

An anaplastic astrocytoma is a grade III tumor. Astrocytomas often contain a mix of cells and cell grades, but brain tumors are graded by the highest grade (most abnormal) cell seen in the tumor. These tumors tend to have tentacle-like projections that grow into surrounding tissue, making them difficult to completely remove during surgery. The word "anaplastic" means malignant, and because of this, treatment for an anaplastic astrocytoma may be more aggressive than treatment for a lower grade tumor.

The treatment options your doctor outlines will be based on the size and location of the tumor, what it looked like under the microscope, if and how far the tumor has spread, any previous treatment, and your general health. Generally, the first step in the treatment of anaplastic astrocytomas is surgery. The goals of surgery are to obtain tumor tissue for diagnosis and treatment planning, to remove as much tumor as possible, and to reduce the symptoms caused by the presence of the tumor. There are some circumstances, such as certain medical conditions or concerns about the location of the tumor, in which a biopsy may be done in place of surgery. The tissue obtained during the biopsy is then used to confirm the diagnosis.

Because the tentacle-like cells of an astrocytoma grow into the surrounding tissue, these tumors cannot be totally removed during surgery. Partial removal can help decrease symptoms; the tissue obtained during that surgery confirms the type of tumor. Radiation is then used to treat the remaining tumor. There are several forms of radiation therapy available — conventional external beam radiation, focused radiation or stereotactic radiosurgery, implanted radiation, or conformal radiation. Your radiation oncologist will determine which is best for your particular tumor.

Some treatment plans include the use of chemotherapy for anaplastic astrocytoma. BCNU, CCNU, procarbazine, cisplatin, and temozolomide are commonly used drugs. Some clinicians recommend the use of chemotherapy prior to radiation; in these circumstances the chemotherapy may reduce the amount of tumor to be treated, and may serve as a radiation sensitizer. Other treatment plans may call for the implantation of biodegradable wafers containing BCNU into the cavity created during tumor removal. Still other physicians choose not to use chemotherapy for the initial tumor, "reserving" it for re-growth if necessary.

Anaplastic astrocytomas tend to recur, and when they do, they may regrow as a higher grade tumor. Treatment is based on the grade of tumor at recurrence.

We offer additional information specifically about anaplastic astrocytoma and glioblastoma multiforme, a grade IV astrocytoma. Please call our office if you would like that information.

ASTROCYTOMA GRADE IV

Also called Glioblastoma Multiforme

"Grade IV astrocytoma," "glioblastoma," "glioblastoma multiforme," and "GBM" are all names for the same tumor. Glioblastomas arise from astrocytes — star-shaped cells which form the supportive, glue-like substance of the brain. These tumors represent about 20% of all primary brain tumors and about 50% of astrocytomas. They are more common in older adults, and affect more men than women. Only nine percent of childhood brain tumors are glioblastomas.

Glioblastomas are generally found in the cerebral hemispheres of the brain, but technically can be found anywhere in the brain or spinal cord. Because the glioblastoma is capable of very rapid growth, the first symptoms are usually due to increased pressure in the brain. Headaches, seizures, memory loss, and changes in behavior are the most common presenting symptoms.

Glioblastomas commonly contain a mix of cell types. It is not unusual for the tumor to contain cystic material, calcium deposits, blood vessels, or a mixed grade of cells. Brain tumors, however, are graded based on the most malignant cell found in the tumor, and any astrocytoma that contains necrotic (dead) cells and an extensive network of blood vessels is generally a glioblastoma. The lack of uniformity from end to end of the tumor makes a glioblastoma one of the most difficult brain tumors to treat. While one cell type may be responsive to treatment, other types may be resistant.

The first step in treating a glioblastoma is surgery to remove as much tumor as possible. Radiation therapy almost always follows surgery or biopsy. There are several different forms of radiation therapy — ranging from conventional external beam radiation to stereotactic radiosurgery to conformal radiation therapy — which might be suggested. Other types of radiation therapy, such as implanted liquid radiation or monoclonal antibodies tagged with radioactive particles, may also be considered.

Chemotherapy might be given before, during or after radiation. The most commonly used drugs for adults are BCNU, CCNU, procarbazine, or temozolomide. Biodegradable wafers containing BCNU may be placed in the cavity created by tumor removal. Other new delivery systems are under investigation. Chemotherapy might also be used in children under the age of three to delay radiation.

Antisense therapies block the messages given off by malignant cells, altering their ability to interfere with the normal growth of surrounding cells. Protease inhibitors, such as marimastat and tamoxifen, block the ability of tumor cells to make the proteins needed for tumor cell reproduction. Angiogenesis inhibitors may be capable of interrupting the blood supply to a tumor, thus controlling tumor growth.

Immunotherapy is the use of the body's own immune system to fight a tumor. There are several research studies focusing on this area of treatment, and many of the programs are open to those with a glioblastoma. Immunotoxins, such as diptheria or pseudomonas, link a toxin to an antibody and carry it to the tumor cells. Interferons are thought to inhibit tumor cell growth by stimulating the immune system; they may also be angiogenesis inhibitors. Other researchers are using gene therapies as a way of controlling tumor growth. In one

method, specially-engineered genes make tumor cells more susceptible to drug therapy. In another method, gene therapy is used to stimulate the body's natural production of immune substances. Gene therapy may also be used to restore the normal function of tumor suppressing genes within tumor cells.

New drugs, new drug combinations, and new ways of delivering those drugs are being studied; these treatments are offered in organized research programs called clinical trials. Many clinical trials are available for glioblastoma — both as initial treatment and as treatment for a recurrent tumor. Many of those clinical trials can be found through the Cancer Information Service at 800-422-6237.

Recurrent tumors can be treated with additional surgery, another form of focused radiation, chemotherapy, or any number of experimental approaches as mentioned above.

Additional information about glioblastoma appears on page 37.

Atypical Teratoid Rhabdoid Tumor (ATRT)

This rare, high grade tumor occurs most commonly in children younger than two years of age. It is generally found in the cerebellum — the lower, back part of the brain which controls balance. These tumors tend to be aggressive and frequently metastasize through the central nervous system. Previously thought to be PNETs (primitive neuroectodermal tumors) or medulloblastoma tumors, ATRTs were recently found to have their own histologic and cytologic features which help a pathologist specifically define this tumor. Treatment generally involves removal of the tumor followed by chemotherapy. Radiation therapy may be considered depending on the age of the child, and whether the tumor has recurred. Clinical trials are underway to help develop chemotherapy drugs effective against this tumor — those clinical trials can be found by calling the Cancer Information Service at 800-422-6237.

Chondroma

This rare, benign tumor tends to arise at the base of the skull, especially in the area near the pituitary gland. A chondroma is generally very slow growing and might be present for a long time before causing any symptoms.

These tumors are composed of cartilage-like cells and are usually attached to the dura mater, the outermost layer of the meninges. A chondroma can grow to a large size, and may occur as a single or as multiple tumors. The malignant form of this tumor is called a chondrosarcoma (see the chondrosarcoma section which follows).

Because it is usually accessible with well-defined margins, surgery might be the only treatment required for a chondroma.

Chondrosarcoma

This very rare tumor arises from bone and is composed of cartilage. It is the malignant variant of the benign chondroma (described above) and tends to spread locally, staying within the same general area. This tumor is generally slow growing and rarely metastasizes, or spreads, to areas farther away. It is most commonly found in the sphenoid bone — the bony ridge running along the back of the eyes — or near the clivus, a bony area at the base of the skull. The chondrosarcoma is more common in adult males.

Standard treatment is surgical removal which might be followed with radiation therapy. Those with a chondrosarcoma may also be eligible for treatment in a clinical trial — an organized research study. Those studies can be found through the Cancer Information Service at 800-422-6237.

Chordoma

The chordoma occurs at the base of the skull in about one-third of patients, or at the end of the spine. It is a benign, slow growing tumor. When found in the spine these tend to be extradural tumors, meaning that they are located on the outside of the spinal cord. However, a chordoma may invade the nearby bone, compressing parts of the brain in the

area. It is not unusual for a chordoma to push into the brainstem or grow into the sinuses. Distant spread is rare. This is an uncommon tumor representing only 0.2% of all primary CNS tumors. Although it is found in people of all ages, chordomas are most frequent in younger and middle-aged adults. The most common symptoms are double vision and headache.

The chordoma is visible on CT and MRI scans, but a biopsy is necessary to determine an exact diagnosis. The skull base location can be very difficult to access, making complete removal of tumors in this area a challenge. A combination of surgery followed by radiation is the standard treatment for tumors located in the skull base. Stereotactic radiosurgery and stereotactic radiotherapy have shown promise, as has the combination of aggressive surgery followed by combined proton-photon beam therapy. Complete surgical resection of visible tumor might be possible for the spinal chordoma.

Choroid Plexus Carcinoma

This tumor, which occurs primarily in children, is the malignant form of the choroid plexus papilloma. It comprises about ten percent of all choroid plexus tumors and typically occurs in one of the lateral ventricles. (The choroid plexus carcinoma is sometimes called an anaplastic choroid plexus papilloma.) These tumors commonly invade, or grow into, nearby tissue and spread widely via the cerebrospinal fluid. Hydrocephalus — a collection of cerebrospinal fluid within the brain — is often present.

Treatment often includes surgery, chemotherapy and radiation therapy. A second surgery might be recommended for recurrent tumors, followed by some form of radiation and/or chemotherapy.

Choroid Plexus Papilloma

The choroid plexus papilloma is a rare, benign tumor most common in children under the age of two. About 3% of the primary brain tumors in children are choroid plexus papillomas. They represent fewer than 1% of all primary brain tumors. The choroid plexus carcinoma is the malignant form of this tumor.

In very young children, the lateral ventricles are the most common location of this tumor. The fourth ventricle is the most common site in adults. Both CT and MRI scans detect these tumors.

The choroid plexus papilloma grows slowly within the ventricles. It eventually blocks the flow of cerebrospinal fluid, causing hydrocephalus and increased intracranial pressure. Headache and other symptoms of increased pressure are common.

The standard treatment is surgery and may be the only treatment required if the tumor is completely removed. Tumor removal relieves the hydrocephalus about half the time. A shunt is required for the other patients. The role of radiation or chemotherapy is still being investigated, but might be recommended for inaccessible or partially resected tumors.

Craniopharyngioma

This is a benign tumor arising from small nests of cells located near the pituitary stalk. Craniopharyngiomas represent 2-3% of all primary brain tumors, and 5-13% of childhood brain tumors. About sixty percent of craniopharyngiomas occur in patients older than sixteen.

Adamantinomatous (ordinary) craniopharyngioma occurs in children and tends to be more cystic than the papillary craniopharyngioma. The papillary craniopharyngioma occurs in adults and is a more solid tumor.

Craniopharyngiomas occur in the sellar region, near the pituitary gland. They often involve the third ventricle, optic nerve, and pituitary gland. These localized tumors grow by expansion and may reach a large size before they are diagnosed. Malignancy and metastasis are unknown.

Increased intracranial pressure due to obstruction of the foramen of Monro, one of the small tunnels through which cerebrospinal fluid exits the ventricles, accounts for many of the symptoms associated with this tumor. Other symptoms result from pressure on the optic tract and pituitary gland. Obesity, delayed development, impaired vision, and a swollen optic nerve are common.

Surgery to remove the tumor is usually the first step in treatment. If hydrocephalus is present, a shunt may be placed during surgery. That shunt will help drain excess cerebrospinal fluid away from the brain. A form of radiation therapy may be suggested if all visible tumor cannot be removed. This may include a focused form of radiation — such as radiosurgery or conformal radiation — or a radiation source may be implanted into the tumor cavity, such as intracavitary use of radioactive phosphorous. In children younger than 3, radiation therapy may be delayed by the use of surgery or hormone therapies. Because this tumor tends to be located close to the pituitary gland which controls hormone balance in the body, an endocrinologist may become involved in the long-term care plan. An endocrinologist is a doctor trained in treating hormone imbalances.

Cysts

Just like a cyst elsewhere in your body, a cyst in the brain is a tumor-like sphere filled with fluid, similar to a balloon filled with water. Cysts may contain fluid, blood, tissue, or tumor cells. There are specific types of cysts; they are named for the type of tissue from which they arose and for their contents. The most common cysts found in the brain are arachnoid, colloid, dermoid, and epidermoid cysts. Each is described below.

ARACHNOID CYST

An arachnoid cyst (sometimes called a leptomeningeal cyst) is an enlarged, fluid-filled area of the subarachnoid space — the space between the arachnoid and pia mater layers of the meninges which form a membrane-like covering around the brain and spinal cord. Arachnoid cysts occur in both adults and children. Their most common locations are in the area of the Sylvian fissure, the cerebellopontine angle, the cisterna magna or the suprasellar region of the brain. The usual treatment is surgery to drain and remove the outermost lining of the cysts. Some surgeons choose to place a shunt to divert the cyst fluid to other areas of the body. Shunting may also be required if the cyst is blocking the flow of cerebrospinal fluid in the brain.

COLLOID CYST

The third ventricle is the most frequent location of the benign colloid cyst. Malignant forms are unknown. This cyst almost always occurs in adults. It is typically attached to the roof of the third ventricle and the choroid plexus. This location may block the flow of fluid through the foramen of Monro, one of the small tunnels through which cerebrospinal fluid exits the ventricles, causing increased intracranial pressure. Headache is the most common symptom.

Various surgical approaches, stereotactic directed cyst drainage or shunting are some of the treatment options for the colloid cyst. Removing this cyst without causing undue damage can be challenging because of its location on/near the third ventricle, and the "best" treatment is dependent on individual patient's anatomy and the configuration of their cyst.

DERMOID CYST

Dermoid cysts likely form during the early weeks of fetal development even though the symptoms may not be noticed for years after birth. As an embryo is developing, the neural tube — the cells which will eventually form the brain and spine — begins to separate from the cells which will become the skin and bones of the face, nose, and vertebrae. A dermoid cyst results when cells that normally belong to the face are diverted to the brain or the spinal cord. That's why the inside of a dermoid cyst often contains hair follicles, bits of cartilage, or sebaceous glands which produce skin oils and fats. On rare occasions, a dermoid cyst may spontaneously open, releasing these oils into the brain or spinal cord.

Dermoid cysts are relatively rare masses to be found in the brain — epidermoid cysts are far more common. However, when a dermoid cyst is found in the brain it is usually a benign mass. These cysts are usually located in the posterior fossa (the lower back portion of the brain) or the adjacent meninges (the thin membranes which form the covering of the brain and spinal cord). Dermoid cysts in the brain tend to occur in children under 10 years old. The lower end of the spine is the more common location in older children and young adults. The cavity of the fourth ventricle and the base of the brain under the surface of the frontal lobes are also common sites.

The standard treatment for a dermoid cyst is surgical removal. If the cyst is unable to be completely removed, it will likely regrow. That growth may be very slow, and it may be years before symptoms would again return.

EPIDERMOID CYST

Also called Epidermoid Tumor

Epidermoid cysts, also referred to as epidermoid tumors, likely form during the early weeks of fetal development even though the symptoms may not be noticed for several decades into life. As an embryo is developing, the neural tube — the cells which will eventually form the brain and spine — begins to separate from the cells which will become the skin and bones of the face, nose, and vertebrae. An epidermoid cyst results when cells that normally belong to the face and bones are diverted to the brain. That's why the inside of an epidermoid tumor often contains remnants of skin cells or tiny pieces of cartilage. On rare occasions, a epidermoid cyst may spontaneously open, releasing these contents into the brain or spinal cord.

Epidermoid cysts occur more frequently in the brain than in the spine, and are a fairly common type of cyst to be found in the brain. They are usually benign, and are most commonly found in middle-aged adults. These cysts tend to be located near the cerebellopontine angle (the area where the top part of the brain meets the brain stem) and near the pituitary gland. Standard treatment is surgical removal. If the cyst is unable to be completely removed, it can re-grow. That growth may be very slow, and it may be years before symptoms would again return.

Dysembryoplastic Neuroepithelial Tumor (DNET)

DNETs are slow growing, benign, grade I tumors. Traditionally seen as similar in appearance and behavior to an oligodendroglioma, recently developed laboratory testing allows pathologists to separate this tumor from other similar appearing tumors. These tumors tend to contain a mix of neurons (nerve cells) and glial (supportive) cells suspended in a mucous-like substance. Although they occur in both adults and children, this tumor tends to be found in people ages twenty to thirty. It is not unusual for the diagnosis to be preceded by a long history of uncontrollable seizures of the partial complex type. DNETs have been occasionally associated with a history of neurofibromatosis type I.

The DNET is most commonly located in a temporal or frontal lobe of the brain. Surgery alone often provides long term control for this tumor, even when the tumor is unable to be completely removed.

Ependymoma

Ependymomas arise from ependymal cells which line the ventricles of the brain and the center of the spinal cord.

EPENDYMOMA

Ependymal cells line the ventricles of the brain and the center of the spinal cord.

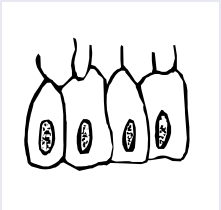

These are relatively rare tumors, accounting for 2-3% of all primary tumors. However, they are the most common brain tumor in children. About one-third of pediatric brain tumors are diagnosed in children under the age of three. Ependymomas are soft, greyish or red tumors which may contain cysts or mineral calcifications. They are divided into four major types: *myxopapillary ependymomas, subependymomas, ependymomas and anaplastic ependymomas*. Many pathologists also assign a number to ependymomas. The grade is based on how much the cells look like normal ependymal cells, although various grading systems exist. The cells of a grade I tumor look somewhat unusual, whereas grade IV tumor cells look definitely abnormal.

Myxopapillary ependymomas tend to occur in the lower part of the spinal column. Subependymomas usually occur near the ventricle. Both of these ependymoma types are uncommon in children. They are slow growing, and are considered to be low-grade or grade I tumors. Ependymomas are the

most common, and are considered grade II tumors. Anaplastic ependymomas are high-grade tumors (grades III or IV) and tend to be faster growing than the low-grade tumors.

The first step in the treatment of an ependymoma is surgery to remove as much tumor as possible. The amount of tumor that can be removed, however, depends on the location of the tumor. Radiation therapy is usually recommended for older children and adults following surgery, even if all visible tumor was removed. If the tumor is localized, radiation therapy is usually given just to that area of the brain. If the tumor has spread, radiation is usually given to the entire brain and spine, with an extra amount of radiation (called a boost) given to the area of the brain where the tumor started. In general, the role of chemotherapy in newly diagnosed ependymomas is not clear, however, it may be used to treat recurrent tumors or to delay radiation therapy in very young children.

We offer additional information specifically about ependymoma and about brain tumors in children. Please call our office if you would like that information.

Gangliocytoma and Ganglioglioma

These rare, benign tumors arise from ganglia-type cells, which are groups of nerve cells. Gangliocytomas (sometimes called ganglioneuromas) are tumors of mature ganglion cells. Gangliogliomas are tumors of both mature nerve and supportive cells.

Tumors arising from ganglia most frequently occur in children and young adults. They represent less than 1% of all primary brain tumors and about 4% of all pediatric brain tumors.

NERVE CELL

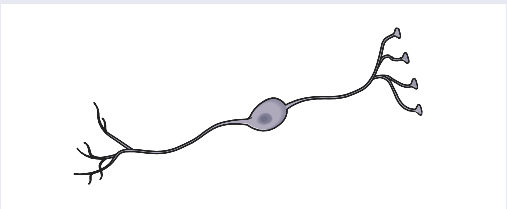

These tumors are most commonly located in the temporal lobe of the cerebral hemispheres and the third ventricle, although they might also occur in the spine. These tumors are small, slow growing, and have distinct margins. Metastasis and malignancy are very rare.

Cyst formation and calcification can be present. Seizures are the most common symptom.

The standard treatment for gangliocytoma and ganglioglioma is surgery.

Germ Cell Tumors

See also the specific type of germ cell tumor

These uncommon tumors represent 1–3% of childhood brain tumors and occur primarily in young people between the ages of 11 and 30. Germ cell tumors arise in the pineal or suprasellar regions of the brain. Included in this type of tumor are the germinoma, the teratoma, the more aggressive embryonal carcinoma and yolk sac (endodermal sinus) tumors, and the choriocarcinoma. Mixed germ cell tumors also exist. Because all these tumors tend to spread via the cerebrospinal fluid (CSF), diagnosis includes evaluation of the entire brain and spinal cord. An MRI scan with gadolinium enhancement and examination of the CSF for the presence of tumor cells is used for that evaluation.

Germ cell tumors are the only primary brain tumors that might be diagnosed by tumor markers found in the cerebrospinal fluid and blood. The markers are alpha-fetoprotein (AFP), placental alkaline phosphatase (PAP) and human chorionic gonadotropin (HCG). More commonly, however, the markers are used to monitor the effectiveness of therapy and to detect recurrence.

Because of its location, a germ cell tumor is often treated with chemotherapy or a combination of radiation and chemotherapy rather than surgery, although a biopsy to establish an exact diagnosis is not uncommon.

Germinoma

The germinoma is the most common type of germ cell tumor in the brain. It typically occurs in the pineal or suprasellar region of the brain. Because it tends to spread via the cerebrospinal fluid, diagnosis includes evaluation of the entire brain and spinal cord. An MRI scan with gadolinium enhancement and examination of the CSF for the presence of tumor cells is used for that evaluation.

The germinoma is the most common tumor of the pineal region representing about 30% of those tumors. Its occurrence is more usual in teen-aged children, and in males more often than females.

Tumors in the pineal region typically cause symptoms indicating increased intracranial pressure. Headache due to obstructed cerebrospinal fluid flow is the most common symptom. If the tumor is in the suprasellar location, symptoms include diabetes insipidus, vision changes, signs of hormonal dysfunction such as fatigue, poor appetite, delayed or absent puberty, and changes in the menstrual cycle.

Surgery for germinoma depends on its accessibility and position relative to critical brain structures. The germinoma is very responsive to radiation and this can be an effective treatment for some patients. Chemotherapy might be the treatment of choice for some newly diagnosed tumors. Chemotherapy can also be useful for recurrent tumors.

Glioblastoma Multiforme (GBM)

Also called "astrocytoma, grade IV"

"Glioblastoma," "glioblastoma multiforme," "grade IV astrocytoma," and "GBM" are all names for the same tumor. Glioblastomas arise from astrocytes, which are star-shaped cells supporting the other cells in the brain. These tumors represent about 20% of all primary brain tumors and about 50% of the gliomas. They are more common in older adults, and affect more men than women. Only nine percent of childhood brain tumors are glioblastomas.

Glioblastomas are generally found in the cerebral hemispheres of the brain, but can be found anywhere in the brain or spinal cord. Because glioblastomas can grow rapidly, the most common symptoms are usually due to increased pressure in the brain and can include headache, nausea, vomiting and drowsiness. Depending on the location of the tumor, patients can develop a variety of other symptoms such as weakness or sensory impairment on one side of the body, seizures, memory or language impairment, and visual changes.

Glioblastomas may arise from a lower grade astrocytoma (grade II or III) or start as a grade IV tumor. Regardless of their origin, all glioblastomas are grade IV tumors because they have several features of rapidly growing tumors — abnormal and numerous blood vessels, as well as dead tissue called necrosis. Since these tumors arise from normal brain they easily intermingle with the normal brain tissue as well as invade and migrate away from the main tumor; however, glioblastoma will rarely spread elsewhere in the body. In addition, several clusters of cells may be resistant to radiation and chemotherapy. All of these factors make these tumors a challenge to treat.

The first step in treating a glioblastoma is surgery to make a diagnosis, relieve pressure, and safely remove as much tumor as possible. Because this tumor has octopus-like tentacles that invade and migrate into the surrounding normal brain, there are no clear edges to glioblastomas. This feature makes them very difficult to remove "completely." If the tumor is located near important structures such as the language center or motor area, the ability to remove most of the tumor may be further limited.

Radiation therapy almost always follows surgery or biopsy. Radiation therapy affects mostly replicating cells and therefore causes more damage to tumor cells than to normal brain cells (most cells in the brain are not actively dividing). The most common type of radiation is called fractionated external beam radiation, meaning that the radiation is given in several treatments over a few weeks. External beam radiation is also called standard radiation or conventional radiation. It is given to the tumor and a margin around it, but not to the whole brain. Other types of radiation sometimes

used for glioblastomas include stereotactic radiosurgery (an intense and focused dose of radiation), brachytherapy (consisting of either implanted radioactive seeds or catheters with temporary radioactive sources in the tumor), liquid radiation in an inflatable balloon instilled after tumor resection, or monoclonal antibodies tagged with radioactive particles.

Chemotherapy may be given before, during or after radiation therapy. Like radiation, chemotherapy affects replicating cells and can have a selective effect on tumor cells. Chemotherapy can also help radiation work more efficiently. Systemic chemotherapy, delivered to the brain through the blood, reaches the tumor cells wherever they are in the brain including those that may not have received radiation. The most commonly used drugs for adults are BCNU, procarbazine, temozolomide (Temodar), or irinotecan. Biodegradable wafers containing BCNU may be placed in the cavity created by tumor removal. New agents, dosages and delivery methods are under investigation. Chemotherapy is often used in children under the age of three to delay radiation.

Another category of drugs that acts differently than chemotherapy and can be used in glioblastoma is "cytostatic" or "biological" agents. These agents interfere with different activities of tumor cells:

- communication with other tumor cells and with the environment or message transmission within the tumor cell (e.g., tamoxifen)
- invasion and migration in the normal brain (e.g., marimastat)
- angiogenesis, the process by which the tumor is building up new vessels to increase its blood supply so it can continue to grow (e.g., thalidomide, endostatin)
- dedifferentiation, the process by which a tumor cell becomes more malignant or different from a normal cell (e.g., 13-cis-retinoic acid).

Immunotherapy uses the body's own immune system to fight a tumor. Several strategies are in study, including:

- use of proteins called cytokines involved in immune system regulation (e.g., interferon, interleukin, TNF)
- use of vaccines with either tumor cells and/or immune cells
- use of proteins called antibodies directed specifically to tumor cells and tagged with either a toxin (e.g., diphtheria, pseudomonas toxins), a drug, or a radioactive compound to destroy tumor cells.

Gene therapy is a very promising and targeted way to treat tumors like glioblastoma. It usually uses a transporter (vector) which is generally a virus. Several strategies are currently under investigation and include:

- genes that prevent tumor cells from replicating and/or cause cell death (apoptosis)
- genes promoting the production of molecules that interfere with mechanisms used by the tumor cells outlined above
- genes that make tumor cells more sensitive to certain drugs
- some viruses specifically-engineered (meaning with gene modification) to replicate only in tumor cells and therefore cause cell death (oncolytic virus).

A major obstacle in gene therapy success is inadequate delivery of the genes and its vector to all tumor cells.

The outcome of glioblastomas not only depends on treatment but also on the patient's age and functional status (how the patient is functioning in daily life and how much impairment is present). Unfortunately, glioblastomas have the potential to recur even with the best treatment. If a recurrence is confirmed the same treatment principles apply. Further surgery, additional forms of radiation (e.g., stereotactic radiosurgery), next-line chemotherapy, biological agents or agents under investigation can all be considered.

We offer additional information about glioblastoma, new treatment options, and family support services. Please contact us to access those services. There are also many clinical trials open to those with either a newly diagnosed or a recurrent glioblastoma; the Cancer Information Service will help you find these trials. CIS can be reached at 800-422-6237.

Glioma

This is a general name for any tumor that arises from the supportive tissue called glia, which help keep the neurons ("thinking cells") in place and functioning well. There are three types of glial cells that can give rise to tumors. An astrocyte (star-shaped cell) will give rise to astrocytomas (including glioblastomas), an oligodendrocyte (cell with short arms forming the insulation of neurons) will give rise to oligodendrogliomas, and lastly, tumors called ependymomas arise from ependymal cells (i.e., the cells that form the lining of the fluid cavities in the brain). Occasionally, tumors will display a mixture of these different cells and are called mixed gliomas.

Names such as "optic nerve glioma" and "brain stem glioma" refer to the location of these tumors, and not the type of tissue that gave rise to them. A specific diagnosis is only possible if a sample of the tumor is obtained during surgery or biopsy.

GLIAL CELLS

Glioma, Brain Stem

Brain stem gliomas usually arise in the "stem of the brain," which contains all the "wires" converging from the brain to the spinal cord as well as important structures involved in eyes movements, face and throat muscle control and sensation. Between 10 and 20% of brain tumors in children are brain stem gliomas. This tumor most often affects children between 5 and 10 years old, but can also be found in adults generally between 30 and 40 years old. Most of these tumors are astrocytomas varying from localized grade I tumors (mostly in children) to infiltrating grade II or III tumors, although many are never biopsy-proven given the high-risk of performing any surgical procedure in that area. However, the diagnosis can usually be based on the MRI scan features.

THE BRAIN STEM: MIDBRAIN, PONS, AND MEDULLA

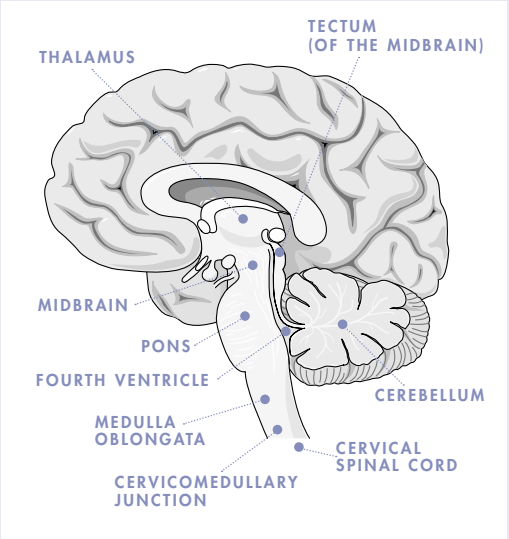

Most of these tumors are classified by their location:

- Upper brain stem (midbrain or tectum)
- Middle brain stem (pons)
- Lower brain stem (cervico-medullary)

and MRI appearance:

- Localized or circumscribed
- Diffusely infiltrating
- Exophytic (meaning the tumor has a knob protruding outside the brainstem)

The majority of brain stem tumors occur in the pons, are diffusely infiltrating, and therefore are not able to be surgically removed. A few of these tumors are localized, and may be reachable for resection. These tumors tend to be very slow growing, not in the pons, and are exophytic — on the outer edges of the brain stem.

The symptoms of a brain stem glioma depend on the location of the tumor. The most common symptoms are related to eye movement abnormalities and cause double vision. Other symptoms include weakness or sensation changes of the face, swallowing difficulty and hoarseness. Weakness, loss/changes in sensation or poor coordination on one side of the body may also occur. The tumor may also block the cerebrospinal fluid circulation resulting in hydrocephalus (dilatation of the fluid cavities in the brain) causing headache, nausea, vomiting and gait unsteadiness.

Treatment of brain stem glioma is dictated by the tumor location, the grade and the symptoms. Surgery may be warranted if a tumor appears circumscribed (contained) or exophytic (on the outside of the brain stem). The goals of surgery are to determine the grade and type of tumor and, sometimes, removal of the tumor. A shunt may also be placed if there is blockage of the cerebrospinal fluid circulation. Radiation therapy may be used early if there are significant symptoms, or it may be postponed until the tumor grows or causes symptoms. A focal type of radiation, such as radiosurgery, can be considered if the tumor appears localized. Chemotherapy is used if the tumor progresses following radiation therapy. Drugs similar to those used to treat glioblastoma may be considered.

Radiation therapy with hyperfractionation (with smaller dose per treatment and many more doses) has been used in children in order to increase the effectiveness of the therapy and decrease side effects. Unfortunately, this has not resulted in significant advantage over standard radiation. Clinical trials using various forms, doses and schedules of radiation therapy for newly diagnosed tumors, and chemotherapy for recurrent tumors are available.

Glioma, Mixed

Mixed gliomas commonly contain a high proportion of more than one type of cell. Most often these tumors contain both astrocytes and oligodendrocytes — these tumors are generally called mixed gliomas or oligoastrocytoma. Occasionally, ependymal cells are also found. The behavior of a mixed glioma tends to be based on the grade of the tumor. It is less clear whether their behavior is closer to that of the most abundant cell type.

Standard treatment for a mixed glioma is similar to that for astrocytoma and oligodendroglioma of the same grade. The treatment plan may includes surgery followed by radiation therapy, particularly if the tumor is high-grade (grade III or IV) although it may also be indicated for lower-grade tumors (grade II). Chemotherapy will generally be used in high-grade tumors. We offer additional information specifically about oligoastrocytoma and oligodendroglioma. Please call our office if you would like that information.

Glioma, Optic

These tumors may involve any part of the optic pathway including the optic nerve right behind the eyeball, the optic chiasm where both optic nerves come together, the optic tracts located close to the brain stem or the optic radiations within the brain. Optic gliomas also have the potential to spread along these pathways. Most of these tumors occur in children under the age of 10. The grade I pilocytic astrocytoma and grade II fibrillary astrocytoma are the most common tumors affecting these structures. Higher-grade tumors may also arise in this location.

Twenty percent of children with neurofibromatosis 1 (NF-1), a genetic disorder affecting the skin and nervous system, will develop an optic glioma. These gliomas are typically grade I, pilocytic astrocytomas. Children with optic gliomas are usually screened for neurofibromatosis (NF) for this reason. Adults with NF-1 generally do not develop optic gliomas.

These tumors may be quiet, causing few or no symptoms. Their placement along the nerves of seeing, however, can cause loss of vision (in one eye or partial vision loss in both eyes depending on the location of the tumor) or strabismus ("crossed eyes"). Hormonal disturbance might also occur causing developmental delay, early puberty and other symptoms.

VISUAL CHANGES WITH TUMORS ALONG THE OPTIC PATHWAY

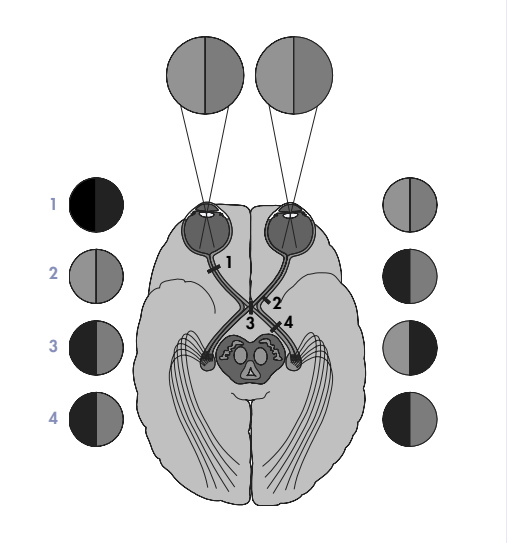

Careful observation may be an option for patients with stable or slow growing tumors. Treatment other than monitoring is based on symptoms or changes seen on the MRI scan. Surgery might be recommended for a growing tumor which involves only the optic nerve. Radiation therapy might be used for a tumor of the chiasm or other pathways. Local radiation therapy and chemotherapy with radiation therapy are used for recurrent tumors. Clinical trials are available for both primary and recurrent tumors.

Gliomatosis Cerebri

This condition is an uncommon primary brain tumor characterized by a diffuse, or broad, spread of glial tumor cells in the brain. This tumor is distinct from other gliomas by its scattered and widespread nature, typically involving two or more lobes of the brain. This tumor could be considered a "widespread low-grade glioma." It also lacks the malignant features (such as abnormal blood vessels' growth and dead tissue) seen with high-grade tumors. The diffuse nature of gliomatosis causes enlargement of any part of the brain it involves including the cerebral hemispheres, or less often, the cerebellum or the brain stem. Symptoms are often nonspecific and can include personality and behavioral changes, memory disturbance, increased intracranial pressure with headache and sometimes seizures. Treatment is less well-defined given the rarity of this tumor. Surgical resection is generally not attempted due to the diffuse nature of that tumor; the diagnosis might be based on biopsy only. Radiation therapy and chemotherapy may be considered.

Glomus Jugulare

See also Paraganglioma

Glomus jugulare tumors are also called paragangliomas. They originate from chemical sensors called chemoreceptors located in the lining of a large vein in the neck called the jugular vein. These tumors are rare, slow growing, usually benign, but can spread to the bone close to the inner and middle ear. This tumor is most often found in people about 50 years old. Most people have symptoms related to the inner ear including hearing loss, abnormal noise in the ear, dizziness, ear pain or bleeding in the external ear canal. Other nerves located close to the jugular vein can be affected and result in facial weakness, hoarseness or swallowing difficulties.

The initial diagnosis of this type of tumor may be made with CT or MRI scanning. These studies show a tumor either at the jugular vein opening at the base of the skull or higher up close to the inner ear canal, cerebellum and brainstem. Cerebral angiography using a dye injected in brain vessels can be helpful in making a diagnosis because this tumor often has a large blood supply. If the tumor "runs in the family," it is not unusual to find multiple tumors in the same person.

Because of the rarity of this tumor the most effective treatment is not well-defined. Surgery appears to benefit young patients with a large tumor causing symptoms. The surgical team often consists of a neurosurgeon and a "head and neck" surgeon. ("Head and neck" is not the same as the "brain." These are separate areas of medicine.) Standard radiation or radiosurgery also appears effective in stabilizing these tumors. Radiosurgery can be used in patients with small tumors or when residual tumor is left after surgery.

Hemangioblastoma

Hemangioblastoma is a benign and slow-growing tumor arising from cells in the blood vessel lining. These cystic tumors tend to have clearly indicted borders and do not infiltrate the surrounding normal tissue. Single or multiple tumors may be present. They are most common in the lowest part of the brain — the posterior fossa, which contains the cerebellum and the brainstem — but can occur in the cerebral hemispheres, the spinal cord or even the retina.

Hemangioblastomas represents about 2% of all primary brain tumors. About 10% of patients with hemangioblastoma have Von Hippel-Lindau disease, an inherited condition that predisposes to this tumor and tumors of the liver, pancreas and kidneys. The tumor can occur at any age but most commonly found in people about 40 years old.

This tumor commonly causes blockage of the cerebrospinal fluid circulation resulting in hydrocephalus (enlarged fluid cavities of the brain) and increased intracranial pressure. It may also compress the cerebellum involved in balance and limbs coordination. The most common symptoms include headache, nausea and vomiting, gait disturbances, and poor coordination of the limbs.

CT or MRI scans can be used to visualize the hemangioblastoma. Angiography is done before surgery to confirm the diagnosis and provide information about the tumor's blood supply.

Surgery is the standard treatment. Incompletely removed tumors or tumors attached to the brain stem might be treated with focused radiation such as stereotactic radiosurgery. Drugs affecting the growth of the blood vessels which feed the tumor (a process called angiogenesis) are being studied for this disease.

For more information about Von Hippel-Lindau disease, contact:

VHL Family Alliance
171 Clinton Road
Brookline, Massachusetts 02445

Phone: 800-767-4845
E-mail: info@vhl.org
Website: www.vhl.org

Hemangiopericytoma

This is a rare grade II or III tumor, different in origin from meningiomas although arising in the same location — the lining of the brain called meninges. These tumors appear to originate in the cells surrounding the blood vessels in the meninges, and this explains the large blood supply within these tumors. They do not invade the brain but have a greater potential than meningioma to recur locally or even spread elsewhere in the body (bone, lung and liver) although the latter does not occur until late in the disease. Hemagiopericytomas affect younger people than meningiomas, and people usually have symptoms for less than a year before diagnosis.

Standard treatment begins with a study of the vessels feeding the tumor (cerebral angiogram) in an attempt to minimize blood loss during surgery. The goal of surgery is to remove as much tumor as possible, yet this is possible in only about 50% of cases. Since these tumors have a tendency to come back, radiation therapy is generally recommended following surgery. Despite best treatment the tumor may recur, and surgery or radiosurgery can be used at that time. Chemotherapy is used if surgery and radiation are not effective, or if the tumor has spread elsewhere in the body. Long-term follow-up with chest x-ray, bone scan, and liver function studies is necessary.

Lipoma

Lipomas are rare, benign tumors composed of fatty tissue. The most common location is in the region of the corpus callosum, but they also occur in other areas in the brain usually close to the midline (the middle part of the brain where the two hemispheres of the cerebral lobes meet). A lipoma may cause no symptoms and is often diagnosed coincidentally when scans are performed for other medical reasons. Some lipomas are associated with other congenital abnormalities of the nervous system. It is diagnosed by either CT or MRI scanning. Conservative treatment is usually recommended since these tumors rarely cause symptoms. Surgery may be suggested in some circumstances.

Lymphoma

Also called CNS Lymphoma, Primary Malignant Lymphoma or Primary CNS Lymphoma (PCNSL)

This disease affects people with healthy immune systems and those whose immune system is not functioning properly — such as organ transplant recipients or people who are HIV positive. CNS lymphoma most commonly originates from B lymphocytes and is classified as non-Hodgkin's (meaning it is different than Hodgkin's disease). The incidence of CNS lymphoma has been increasing over the past 20 years; it now represents between 0.5% and 2% of all primary brain tumors.

Lymphoma occurs most often in the cerebral hemisphere but may also involve the cerebrospinal fluid, the eyes or the spinal cord. In addition, a few people may have evidence of lymphoma elsewhere in the body. It is not unusual for this tumor to be found in multiple places in the cerebral hemisphere as it does have the potential to spread throughout the central nervous system. CT or MRI scans are used to diagnose the presence of this tumor, but a biopsy is required for confirmation since other types of tumor, infections or inflammatory disorders may look the same on the scan. A spinal tap to screen for tumor cells in the cerebrospinal fluid might be performed as long as there is no indication of increased intracranial pressure. Examination of other parts of the body, including the eyes, is often recommended to determine if the tumor has spread.

The most common symptoms of CNS lymphoma include personality and behavioral changes, confusion, symptoms associated with increased intracranial pressure (headache, nausea, vomiting, drowsiness), weakness on one side of the body and seizures. Problems with eyesight, such as blurred vision, floaters or double vision may also occur.

Since the tumor may be widespread in the brain, a biopsy is often enough for diagnosis. A resection (surgical removal of the tumor) may only be performed if there is significant pressure. After the diagnosis of lymphoma is confirmed, steroids are used to control brain swelling; this may result in the immediate disappearance of the tumor on a subsequent scan. Lymphoma responds very well to treatments such as radiation or chemotherapy. Radiation therapy has been the standard therapy for many years. Chemotherapy can be used before or after radiation, or in place of radiation to provide greater control. If the peron has no or minimal neurological symptoms, s/he may be treated with an intravenous chemotherapydrug called methotrexate, and radiation may be deferred. Tumor regrowth, if it occurs, may be treated with the same chemotherapy or another drug may be used. Radiation to the entire brain is used for patients with significant impairment of their functions or at the time of tumor recurrence.

Medulloblastoma (MDL)

Medulloblastoma represents 15-20% of pediatric brain tumors. In addition, about 20% of these tumors occur in adults. Medulloblastoma is always located in the cerebellum.

Medulloblastoma is a fast-growing, high-grade tumor which frequently spreads to other parts of the central nervous system. Given its location — close to one of the fluid cavities of the brain called the fourth ventricle — the tumor may also extend into that cavity, block the cerebrospinal fluid circulation, or send tumor cells through the spinal fluid to the spine. It is uncommon for medulloblastomas to spread outside the brain and spinal cord.

The most common symptoms of medulloblastoma, particularly in young children, include behavioral changes, symptoms of increased intracranial pressure such as headache, nausea, vomiting and drowsiness, gait unbalance and poor coordination of the limbs. Unusual eye movements may also occur.

Treatment consists of surgical removal of as much tumor as possible. Testing will also be done to check for possible tumor spread — this would include an MRI of the spine and a cerebrospinal fluid analysis. For older children, adults without evidence of spread and those for whom most of the tumor has been removed, radiation to the tumor area followed by a lower dose of radiation to the entire brain and spinal cord follows surgery. Very young

LOCATION FOR THE CEREBELLUM

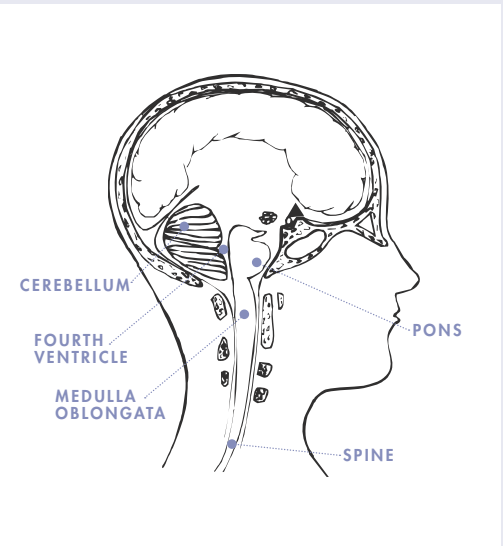

children are often treated with chemotherapy instead of radiation to defer its use until they are older.

"High-risk patients," including children younger than three, those with tumor remaining following surgery, or those with evidence of spread to the spinal fluid or the brainstem may benefit from the addition of chemotherapy. The most commonly used agents include a combination of CCNU and vincristine with either cisplatin or a steroid. Recurrent tumors might require a second surgery and chemotherapy.

Meningioma

These tumors arise from the "arachnoid mater" — one of the layers of the meninges (the lining of the brain). Meningiomas represent about 27% of all primary brain tumors and occur most frequently in middle-aged women. The majority of meningiomas are benign, grade I, slow-growing tumors which are localized and non-infiltrating. Meningiomas are most often located between ("parasaggital meningiomas") or over ("convexity meningiomas") the cerebral hemispheres, at the base of the skull, and in the back, lower part of the brain called the posterior fossa. They occur less frequently in the spine. Most often a single tumor is found, but multiple meningiomas also occur. Risk factors for meningioma include prior radiation exposure to the head, and a genetic disorder called "neurofibromatosis type 2" (see section on NF) which affects the nervous system and the skin; however, meningiomas occur in people who have no risk factors.

MENINGES

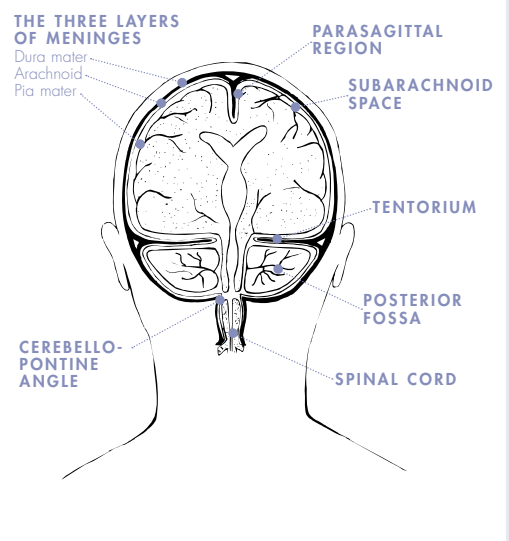

A variety of symptoms are possible, depending on the tumor's location. The most common indications are headache, weakness on one side, seizures, personality and behavioral changes, and confusion.

The benign meningioma (grade I) is slow growing with distinct borders. Because it grows slowly, it can grow quite large before symptoms become noticeable. Symptoms are caused by compression rather than by the tumor growing into brain tissue. If the tumor is accessible, the standard treatment is surgery to remove the tumor, the portion of the dura mater (the outermost layer of the

COMMON LOCATIONS OF MENINGIOMAS

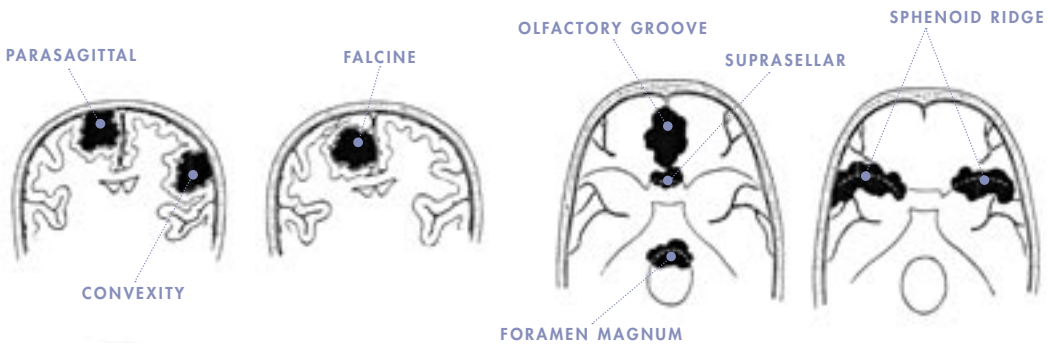

Burger, Scheithauer, and Vogel. *Surgical Pathology of the Nervous System and Its Coverings*. Fourth Edition. Churchill Livingstone, New York, 2002. Diagram reproduced with permission.

meninges) to which it is attached and any bone that is involved. Total removal appears critical for long-term tumor control. Radiation therapy or radiosurgery might be of value if the tumor is not entirely resected. For some patients, surgery may not be recommended. For those with no symptoms (when they have been diagnosed coincidentally), those with minor symptoms of long duration and those for whom surgery would be risky, long-term close observation with scans may be advised. An alternative includes focused radiation, or stereotactic radiosurgery.

The atypical meningioma (grade II) has a middle range of behavior. These tumors are not clearly malignant but they may invade the brain, have a tendency to recur and are faster growing. The diagnosis and grade are determined by specific features that can be seen under the microscope. Radiation therapy is indicated after surgery, particularly if any residual tumor is present.

Anaplastic or malignant meningiomas (grade III) and papillary meningiomas are malignant and tend to invade adjacent brain tissue.They represent less than 5% of meningiomas. Radiation therapy is clearly indicated following surgery regardless of whether residual tumor is present.

Meningiomas may recur, either as a slow-growing tumor or sometimes as a more rapidly growing, higher-grade tumor. Recurrent tumors are treated similarly, with surgery followed by either standard radiation therapy or radiosurgery regardless of the grade of the meningioma. Chemotherapy and biological agents are being studied for recurrent meningioma. Hormone therapy does not appear effective.

We offer additional information about Meningioma. Please call our office if you would like that material.

Metastatic Brain Tumor

A metastatic, or secondary, brain tumor is formed by cancer cells from a primary cancer elsewhere in the body which spread to the brain. In most situations, the primary cancer is diagnosed before it spreads to the brain, but in some circumstances the brain tumors are found the same time or before the primary cancer is found. Cancers that frequently spread to the brain include:

- Lung cancer
- Breast cancer
- A malignant skin cancer called melanoma
- Kidney cancer
- Colon cancer

We offer additional information specifically about metastatic brain tumors. Please call our office if you would like that material.

Neuroblastoma, Cerebral

Neuroblastoma most commonly occurs outside the central nervous system, in the abdomen and chest. It is part of the family of tumor called "PNET." When found in the brain, these are usually malignant, rapidly growing tumors occurring in the cerebral hemisphere. They commonly cause increased pressure within the brain, seizures or weakness on one side. Like the PNET, it has the potential to spread throughout the central nervous system via the cerebrospinal fluid. The assessment and treatment are identical to other PNET and outlined in that section.

Neurocytoma, Central

This rare, grade II tumor typically occurs in the fluid cavities of the brain called the lateral ventricles in the region of the foramen of Monro (the area where the left and the right lateral ventricles come together), and occasionally extends into the third ventricle as well. The central neurocytoma contains mature cells similar to normal neurons — the "thinking cells" of the brain — although their exact cell of origin is unknown. Central neurocytoma is most common in young adult males. These tumors usually block the cerebrospinal fluid circulation causing hydrocephalus (dilatation of the brain fluid cavities). Resulting symptoms are those associated with increased intracranial pressure, such as headache, nausea, vomiting, drowsiness. Seizures may also occur.

Standard treatment is surgery, which is often successful; however, excessive bleeding can limit the extent of tumor removal. The role of

radiation therapy is unclear; however, if the tumor has more aggressive features or if the tumor recurs, radiation therapy may be recommended.

Neurofibromatosis (NF)

The term neurofibromatosis refers to two different genetic diseases characterized by skin abnormalities and nervous system tumors. Neurofibromatosis type I, also called NF-1 or Von Recklinghausen's disease, is the more common of the two disorders. It causes tumors of the nerves, called neurofibromas, throughout the body and often visible underneath the skin. It also causes skin discolorations called "café-au-lait" spots as well as freckles in the arm pits and groin regions. Other nervous system tumors can be associated with NF-1; these occur in approximately 10% of patients and include optic pathway gliomas (usually pilocytic astrocytoma), cerebral hemisphere, posterior fossa (brain stem and cerebellum), and low-grade astrocytomas in the spinal cord.

NF-2-associated nervous system tumors may include tumors of the hearing nerve (acoustic neuromas or vestibular schwannoma) typically on both sides, meningiomas, schwannomas of the spinal root of the nerves, and ependymomas (spinal cord or brain).

The predisposition to tumor formation in both disorders is related to genetic abnormalities which interfere with a protein that normally regulates and prevents tumor formation.

Extensive information about neurofibromatosis is available from:

The National Neurofibromatosis Foundation, Inc.
95 Pine Street, 16th Floor
New York, New York 10005

Phone: 800-323-7938
E-mail: nnff@nf.org
Website: www.nf.org

or

Neurofibromatosis, Inc.
9320 Annapolis Road, Suite 300
Lanham, Maryland 20706

Phone: 800-942-6825
E-mail: info@nfinc.org
Website: www.nfinc.org

Oligodendroglioma

These tumors arise from oligodendrocytes, one of the types of cells that make up the supportive, or glial, tissue of the brain. Under the microscope these tumor cells seem to have "short arms" or a fried-egg shape as opposed to astrocytomas, which have "long arms" or a star-like shape. Oligodendrogliomas can be low-grade (grade II) or high-grade (grade III also called anaplastic). Sometimes oligodendrogliomas may be mixed with other cell types. These tumors may also be graded using an "A to D" system which is based on microscopic features such as the appearance of the cell nucleus, the number of blood vessels, and presence or absence of dead tissue called necrosis. The grade denotes the speed with which the tumor cells reproduce and the aggressiveness of the tumor.

OLIGODENDROCYTE

Oligodendrocytes are one of the types of cells that make up the supportive, or glial, tissue of the brain.

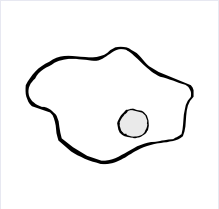

Oligodendrogliomas occur most frequently in young and middle-aged adults, but can also be found in children. The most common location is the cerebral hemisphere, with about half of those tumors being found in the frontal lobe. Seizure is the most common initial symptom, particularly in low-grade tumors.

Standard treatment for accessible tumors is surgical removal of as much tumor as possible. Biopsy alone may be performed for inaccessible tumors — those that cannot be surgically removed. The tumor sample removed during a biopsy is used to confirm the diagnosis and the grade of tumor.

For low-grade oligodendroglioma that appear on the MRI scan after surgery to have been completely resected, close observation with MRI may be recommended. If some of the tumor remains after surgery (this is called "residual" tumor), radiation therapy appears to be indicated although the best timing

— immediately or at tumor progression — is being determined in clinical trials. For anaplastic oligodendroglioma, a combination of radiation therapy and chemotherapy such as PCV (procarbazine, CCNU and vincristine) or temozolomide is indicated. Recurrent low-grade oligodendrogliomas can be treated with surgery, radiation therapy (if not given initially), or chemotherapy. Recurrent anaplastic oligodendroglioma may be treated with surgery and/or chemotherapy. Clinical trials are available for newly diagnosed and recurrent, low-grade or high-grade oligodendrogliomas.

We offer additional information about oligodendroglioma. Please call our office if you would like that material.

Pineal Region Tumors

The pineal gland is located at the rear of the third ventricle — one of the fluid cavities of the brain. Pineal region tumors represent less than 1% of all primary brain tumors; however, 3% to 8% of childhood brain tumors occur in this area. Several tumor types may occur in this area:

- Germ cell tumors including germinoma (tumor similar to other occurring in testes or ovaries), and non-germinoma (including several such as teratoma, endodermal sinus tumor, embryonal cell tumor, choriocarcinoma and mixed tumors)
- Pineal cell tumors including pineocytoma, pineoblastoma, and mixed tumor
- Other tumors including meningioma, astrocytoma, ganglioglioma, and dermoid cysts. *Please see these individual tumor types for additional information.*

PINEAL TUMORS
PINEOCYTOMA
PINEOBLASTOMA
MIXED PINEAL TUMOR

These tumors originate from normal cells of the pineal gland — a gland located in the center of the brain involved in the secretion of specific hormones. The pineocytoma is a slow-growing, grade II tumor. Pineoblastoma is the more aggressive, grade IV, malignant counterpart. A grade III intermediate form has also been described. These tumors tend to occur in young adults between the age of 20 and 40 years. About 10-20 % of the tumors, particularly the pineoblastoma, have the potential to spread through the cerebrospinal fluid. This usually occurs late in the disease. The tumors, however, rarely spread elsewhere in the body.

Symptoms are most often due to obstruction of cerebrospinal fluid flow and involvement of the eye movement pathways. Headache, nausea and vomiting, and double vision are common.

CT and MRI scans are used to visualize the tumor and determine if it has spread. If a biopsy or surgery is not considered, cerebrospinal fluid analysis may be used to rule out other tumor types occurring in the same area.

Surgery may be possible in some individuals to determine the tumor type and to remove part of the tumor. If surgical removal is not possible, biopsy may be considered — depending on the risks involved — for purposes of obtaining a tissue sample for pathological examination and confirmation of the diagnosis. Some patients require placement of a shunt to relieve the cerebrospinal fluid obstruction.

The standard treatment for these tumors is radiation therapy. Conventional radiation therapy to the pineal region is standard, although a form of focused radiation may be considered. Radiation of the entire brain and spinal cord is generally recommended for pineoblastoma. Chemotherapy may also be considered, particularly if the tumor has spread or if the tumor regrows.

Pituitary Tumors

The pituitary gland is involved in the secretion of several essential hormones. Tumors arising from the pituitary gland itself are called adenomas. Adenomas are benign and slow growing tumors. These tumors represent approximately 10% of primary brain tumors. Pituitary adenomas occur at any age but incidence increases with age. Women are more affected than men, particularly during childbearing years.

Most pituitary adenomas grow in the front two-thirds of the pituitary gland, which is called the adenohypophysis. The tumors are classified as "secreting" or "non-secreting." A "secreting tumor" produces excessive

PITUITARY GLAND

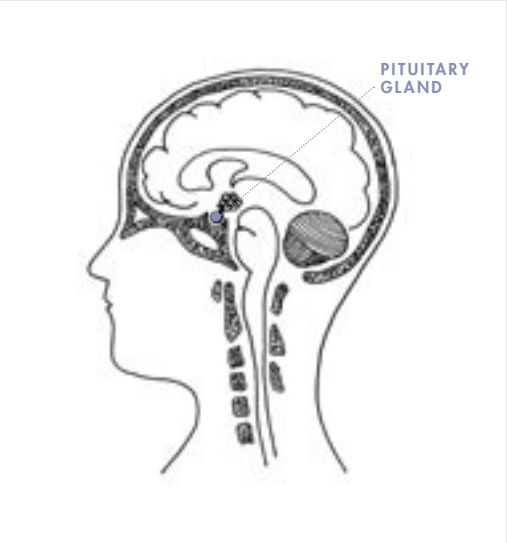

amounts of hormones. The majority of pituitary adenomas are secreting tumors, and are further classified by the hormone(s) being secreted.

Symptoms are caused by the growing tumor pushing on surrounding structures, by excessive hormone production, or by impaired hormone production. The hormones most commonly affected include growth hormone (which regulates body height and structure), prolactin (which controls lactation, or milk production), the sex hormones (which control the menstrual cycle and other sexual functions), thyroid gland hormones, adrenal gland hormones and vasopressin (which is involved in water and electrolyte balance). Pressure on surrounding structures most commonly causes headache, visual impairment, and behavioral changes.

MRI scan is used to determine the tumor size and position in relation to other brain structures. Several blood tests can be performed to determine which hormones are elevated or reduced.

Because hormones affect other parts of the body, treating a pituitary tumor is a team effort involving many specialists including a neurosurgeon, an endocrinologist and an ophthalmologist. Usually therapy includes surgery for tumor removal using an approach through the nose and sinuses. However, for a small prolactin-secreting pituitary adenoma, the drug, bromocriptine, may be used to reduce tumor size without surgery. Other tumor-shrinking drugs may be used after surgery depending on the type of hormone the tumor is secreting. Radiation therapy is used for a persistent or recurrent tumor that is not responding to drugs (if the tumor is secreting). For non-secreting tumors, radiation may be used following a partial removal or if the tumor was invasive. Replacement hormone therapy is often prescribed following surgery and/or radiation.

The pituitary carcinoma is the rare malignant form of the pituitary adenoma. It is diagnosed only when there is proven spread (metastases) inside or outside the nervous system. Symptoms are identical to those of the adenoma; this tumor may also secrete a variety of hormones. Treatment may include surgery, radiation therapy, hormone therapy, and chemotherapy.

PNET — Primitive Neuroectodermal Tumor

PNET is a name used for tumors which appear identical under the microscope to the medulloblastoma, but occur primarily in the cerebrum. PNET is used by some to designate tumors such as the pineoblastoma, polar spongioblastoma, medulloblastoma and medulloepithelioma. With the exception of the medulloblastoma, all of these are very rare tumors.

PNETs most frequently occur in very young children. The tumors contain undeveloped brain cells, are highly malignant, and tend to spread throughout the central nervous system.

PNETs commonly contain areas of dead tumor cells (necrosis) and cysts. Laboratory tests help differentiate this tumor from other types. CT scans can show cysts and areas of calcification which are common in PNETs. Surrounding edema is uncommon. MRI scans can provide an indication of tumor size.

Because they tend to be large tumors, symptoms of increased intracranial pressure and mass effect are usual. Seizures are common.

Surgery is the standard initial treatment for these tumors. Because of their large size and tendency to spread, as well as their extensive

blood supply, total surgical removal is rarely achieved. In children older than three and in young adults, radiation therapy routinely follows surgery, with delivery to the entire brain and spine. Doses are similar to those used for medulloblastoma. Younger children are often treated with chemotherapy instead of radiation therapy, until they are older.

The chemotherapy used for medulloblastoma might also be effective against a PNET. Many clinical trials using chemotherapy and combinations of therapy are available for the medulloblastoma and PNET.

Pseudotumor Cerebri

Also called Primary or Idiopathic Intracranial Hypertension.

The cause of this condition is unknown, but it is not due to a brain tumor. Pseudotumor cerebri literally means "false brain tumor" since there is increased pressure of the spinal fluid, which causes symptoms of increased intracranial pressure as with a tumor. It is most common in young or middle-age individuals.

Headaches, vision changes, and other symptoms of increased intracranial pressure are usually present. Diagnosis is generally confirmed by a spinal tap which measures spinal fluid pressure. Scans are used to be sure an actual tumor does not exist.

Treatment consists of relieving the symptoms and saving vision. Pressure may be controlled by medications which reduce the production of cerebrospinal fluid. Vision will be closely monitored during treatment. If vision is threatened, surgery may be considered to decrease pressure on the optic nerves. Or, a shunt may be placed to move spinal fluid to another area of the body.

For more information on pseudotumor cerebri, contact:

Intracranial Hypertension Research Foundation
6517 Buena Vista Drive
Vancouver, WA 98661

Phone: 360-693-4473
Email: info@IHRFoundation.org
Website: www.ihrfoundation.org

Recurrent Tumors

Many tumors cannot be removed completely during surgery because they have invaded the surrounding normal tissues. Some tumors such as low-grade gliomas (astrocytomas and oligodendrogliomas) and meningiomas have the potential to recur as higher-grade or more aggressive tumors. If they recur, a second surgery may be indicated. Conventional radiation therapy can be given if it was not used initially. A form of focused radiation therapy, such as radioactive implants or stereotactic radiosurgery might be recommended if conventional radiation therapy has already been given. Chemotherapy is frequently used to treat recurrent tumors. Clinical trials with chemotherapy and biologic therapies are available, particularly for recurrent high-grade gliomas.

Schwannoma

See Acoustic Neuroma

Skull Base Tumors

Tumors located along the bones that form the bottom of the skull or along the bony ridge in back of the eyes are called skull base tumors. These tumors are most often chordomas, meningiomas, glomus jugulare, schwannomas or metastatic tumors.

SKULL BASE

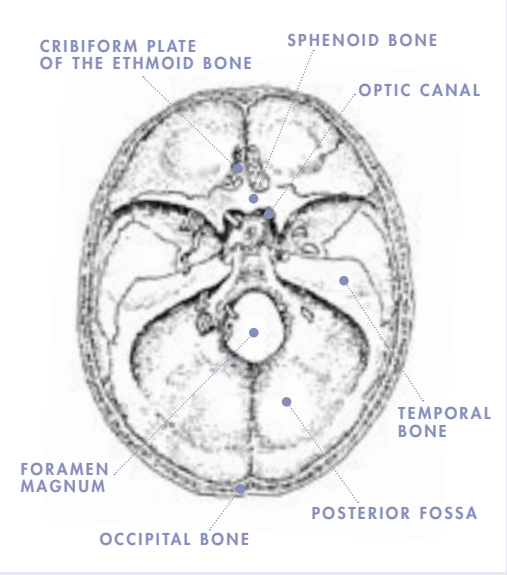

Skull base tumors are diagnosed by MRI or CT scans. Treatment depends on the type and location of the tumor, and well as its surgical accessibility. Newer surgical tools and stereotactic techniques help the neurosurgeon remove large portions of these tumors. A team approach might be used with extensive tumors: a neurosurgeon, an ear, nose and throat (otorhinolaryngology) specialist, a surgeon with training in cranio-facial surgery, and/or a plastic surgeon.

Outcome depends on the extent of tumor removal and the type of tumor. Recurrent tumors might be treated with a second surgery or focused radiation such as stereotactic radiosurgery. Radiation might also be used for partially removed or metastatic tumors.

Spinal Cord Tumors

The types of tumors found in the spine vary by location. Tumors commonly found on the outermost layer of the spinal cord lining, called the dura mater or the epidural area, include metastases from cancers which began elsewhere in the body as well as cancers which tend to be found near the spinal cord, such as sarcoma, neuroblastoma, and multiple myeloma. Tumors found within the dura mater but located outside the actual spinal cord substance (intradural/extramedullary) include meningioma, schwannoma, neurofibroma, and other rare tumors. Finally, tumors arising within the spinal cord substance (intramedullary) include astrocytoma, ependymomas, and less commonly, metastases.

CROSS SECTION OF VERTEBRA AND SPINAL CORD

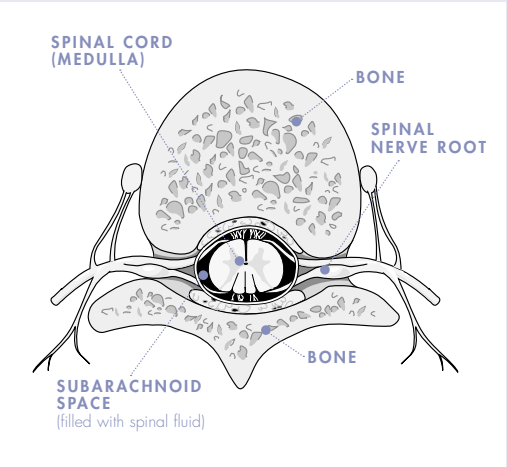

Some symptoms of spinal tumors are due to compression of the spinal cord and usually have a gradual onset. Pain and leg weakness are the most common. If the tumor infiltrates the spinal cord, pain is less common and weakness, sensory impairment, and bladder control difficulty are more often seen.

Treatment of spinal tumors depends on whether the tumor is primary or metastatic, its location and the type of tumor. Epidural tumors are usually treated with radiation with or without surgery. Surgery is the standard treatment for intradural, extra-medullary tumors arising in the spinal canal. Intramedullary tumors may be treated with surgery and radiation may be indicated if residual tumor is left or if the tumor is high-grade.

SPINE

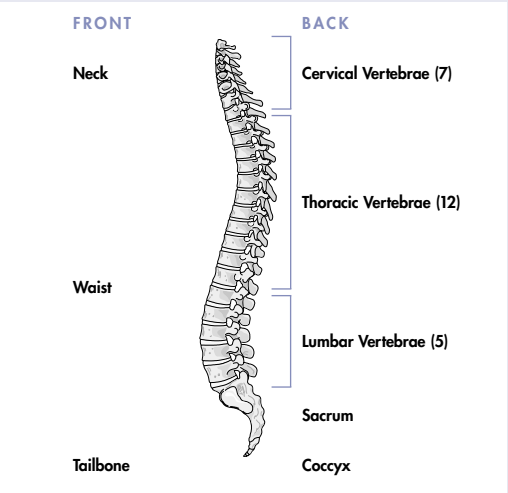

Teratoma

A teratoma is characterized by the presence of the tissue types within the tumor — the tissue can be "mature" (developed cells) or immature (undeveloped). The mature teratoma is a rare, benign germ cell tumor which most frequently occurs in male infants and children. Teratomas represent 18-20% of all germ cell tumors. They often contain calcium, cysts, fat and other soft tissues. Teratomas are most frequently found in the rear of the third ventricle near the pineal gland and above the pituitary gland. This germ cell tumor is the least likely to spread via the cerebrospinal fluid.

Teratomas are the most common brain tumor in newborns. The majority of teratomas occur in children and adolescents. The symptoms vary with the location (see sections on pineal region tumors and pituitary tumors). MRI scan and evaluation of the cerebrospinal fluid for tumor cells help determine if the tumor has spread.

Because obstruction of cerebrospinal fluid circulation occurs in most patients with pineal region tumors, a shunt is often needed to reduce the size of the ventricles before any other treatment can be performed. Surgery is the standard treatment for accessible tumors and can be curative. If surgery is not practical, a biopsy to establish an exact diagnosis may be possible. Radiation therapy may follow surgery or be used for inoperable or partially removed tumors particularly if immature. For children under the age of three, chemotherapy to delay radiation might be recommended.

Toxoplasmosis

This is an infection of the central nervous system caused by a small parasite, Toxoplasma gondii. The parasite is found in the intestines of cats and in uncooked meats. Most people can be exposed to this parasite and never develop symptoms. At risk for severe disease are individuals with compromised immune systems such as AIDS patients, those who have undergone organ transplants, and those who, for other reasons, have an abnormal immune system.

The disease is suspected when seen on MRI or CT scans, but may also appear similar to metastases or primary CNS lymphoma. The disease is usually diagnosed by a 2-3 week trial of drug treatment followed by a scan to assess response. If growth or no response is seen, a biopsy is performed.

Treatment consists of drugs aimed at controlling the infection, including anti-parasitic agents. Drug treatment may continue indefinitely in people with AIDS because of the likelihood of recurrence. Blood tests are used to monitor drug levels. Steroids can be given to control swelling of brain tissue.

Tuberous Sclerosis (Bourneville's Disease)

Tuberous sclerosis is a hereditary disorder affecting the nervous system and the skin as well as other organs. It is an autosomal dominant genetic disorder meaning the child has a fifty-fifty chance of inheriting tuberous sclerosis if a parent has this disorder. In addition, this disease may result from a sporadic mutation (the first case in a family) in 50–60% of patients. Tuberous sclerosis becomes obvious in childhood when seizures occur and skin nodules appear on the face.

Subependymal giant cell astrocytoma is the brain tumor associated with tuberous sclerosis. It often occurs near the foramen of Monro (the narrow channel, also called the interventricular foramen, between the lateral ventricles and the third ventricle through which cerebrospinal fluid flows). This tumor occurs in 5–7% of patients with tuberous sclerosis. Management of this tumor includes a shunt to relieve the cerebrospinal fluid obstruction but surgery is the cornerstone of treatment. Radiation and chemotherapy have no role.

Continuing follow-up for tuberous sclerosis and genetic screening for family members is available through tuberous sclerosis clinics.

For more information on tuberous sclerosis, contact:

National Tuberous Sclerosis Alliance
801 Roeder Road, Suite 750
Silver Spring, Maryland 20910

Phone: 800-255-6872
Email: info@tsalliance.org
Website: www.tsalliance.org

Chapter 7

Seizures

Seizures are common symptoms of a brain tumor. For some people, a seizure may be the first clue that something unusual is happening in their brain.

Seizures might be caused by a brain tumor or the surgery to remove it. Seizures can also be totally unrelated to a brain tumor. For example, an injury to the head, a stroke, alcohol or drug withdrawal, and fever can all cause seizures. Or, the cause may be unknown.

About 60% of all brain tumor patients will experience a seizure at least once during their illness. Seizures are particularly common with slow growing gliomas, meningiomas located in the convexity of the brain, and with metastatic brain tumors. Sometimes, seizures help alert the doctor to the presence of a tumor.

Most seizures can be controlled with medications called antiepileptic drugs (AED's).

Understanding Your Disease

For many people, understanding is the foundation for coping. Arming yourself with information, understanding as much as you can about the options open to you, and making an informed decision can greatly increase your comfort level.

Begin by listening carefully to your doctors and nurses when they explain your illness and treatment options. They are the best source of information about *your* brain tumor. Don't be afraid to ask questions. Most healthcare professionals want patients to be knowledgeable so they can be active members of their treatment team.

You probably have lots of questions. List them in a notebook, placing the most important questions at the top of the list. Bring your questions to your doctor and jot down the answers. It can be helpful to have someone with you. A relative or friend can provide moral support and also help you remember what was said. If it's okay with your doctor, bring a tape recorder with you. You will then be able to listen to the doctor again in the comfort of your own home.

During your doctors' visits, ask for written information about your brain tumor, your symptoms, suggested treatments, and your medications. Before you leave the doctor's office, make sure you understand any instructions you were given. For example, do you have another appointment? If so, when is it? If you are scheduled to have additional tests, do you know when and where to go? Ask the nurse to write important dates and instructions in your notebook.

Telling Family and Friends

Many people find that it helps to share their news with others.

Telling your family and friends you have a brain tumor isn't easy. If you are uncomfortable telling them, consider having a care conference with your doctor and invite the primary members of your family. When you speak with your family, remember that written information about brain tumors is available and can help explain your situation more easily. Like you, your family needs time to understand the diagnosis. A family that understands your illness and the options available to you has the opportunity to be supportive and helpful unlike an uninformed, or misinformed, family.

Social workers can help you find ways to share your feelings with your family, and help you and your family cope. Most hospitals have social work departments. You can also find social workers at community centers, government health agencies and schools.

If you are a parent with young children and you have a brain tumor, try to anticipate your children's concerns. Children use their imaginations to fill in the gaps; their fantasies can cause undue fears and anxieties. Give children information in words they understand. Use their questions as a guide to the amount of information they want. Be prepared for questions that aren't easily answered; reply honestly and simply. Young people often have remarkable insight and can be a source of great comfort.

TALKING WITH CHILDREN

These sample explanations can be adapted for conversations with your children. Change the phrases to match your situation.

"The doctor wants to do some tests to find out why you are getting sick to your stomach and having headaches…"

"An MRI scan takes picture of your brain, but it cannot see what you are thinking."

"A brain tumor is a lump in the brain that doesn't belong there. The doctor is going to operate and take it out."

"No one knows for sure what causes a brain tumor. They just happen. But we do know that nothing you did, or thought, or said caused the tumor. We also know that you don't 'catch' brain tumors from other people."

"Would you like to talk about this? Is there anything you would like to ask?"

Above all, reassure your children they are loved and will be taken care of.

For additional suggestions and explanations children can understand, please visit our children's web site — ABTA Kids — at www.abta.org/kids/home.htm.

HOW TO HELP SOMEONE DURING A SEIZURE

Once started, a seizure cannot be stopped abruptly. Most will end naturally. If you have never seen someone have a seizure, it can be an alarming experience. If you understand what is happening, however, you'll be knowledgeable about what to do.

First, make sure the person is breathing. Loosen clothes around the neck. If the person is having trouble breathing, immediately call for emergency help. Most of the time, a person having a seizure requires no assistance other than caring observation.

If the person appears to be breathing well on his own, take a moment to clear the area of sharp objects or anything else that could be dangerous. If possible, help the person lie on his side. This helps keep their airway open. Protect the patient's head from being bumped if he is having a generalized seizure. Do not put anything in the person's mouth. Do not attempt to restrain a person's limbs during a seizure as this may result in an injury such as a dislocation.

Most seizures last several minutes. After the seizure ends, allow time for the person to recover. He may be confused for a few moments — this is normal. Help re-orient him. Tell him who you are, where he is, and what happened. Help him find a place to rest until he feels like himself again.

Call for emergency assistance if:

- he is having difficulty breathing
- the person injures himself
- the seizure lasts more than 5 minutes
- a second seizure immediately follows

Myoclonic seizures
Myoclonic seizures cause single or multiple muscle twitches, jerks or spasms.

Tonic-clonic (grand mal) seizures
Tonic-clonic (grand mal) seizures are common in people with low grade gliomas but can occur with all gliomas. The seizure begins with a sudden outburst and then a loss of consciousness. This is followed by tonic (twitching) and clonic (relaxing) muscle contractions. During this time the person might bite his tongue, lose control of body functions, and take very shallow breaths. This usually lasts for two or three minutes and is followed by limpness. When the person regains consciousness he or she may be sleepy, have a headache, be confused, and/or have sore muscles. Most people are able to return to their normal activities after resting. If the seizure begins again, call for emergency assistance.

Treatment

Seizures may be controlled in three ways. The most common is with drugs. The second method is surgery. The third method is a special diet, called a ketogenic diet. Sometimes, a combination of methods is used.

MEDICATIONS

Medications are the most widely used method of controlling seizures. The medications are prescribed to prevent seizures or decrease their frequency. They are called antiepileptic medications, and many choices are available. The type your doctor prescribes for you depends on your seizure history as well as the type of seizures you experience.

SURGERY

Surgery to remove the tumor may also stop your seizures. If that occurs, the factor that was irritating the brain's electrical system was removed. Or, using sophisticated brain mapping techniques, the neurosurgeon may be able to define the exact area of the brain causing the seizures and surgically remove it.

KETOGENIC DIET

The ketogenic diet is used to treat epilepsy (recurrent seizures) in children, especially if seizure medications are not effective. The diet is based on a very high intake of fat which causes a chemical imbalance in the body

called "ketosis." Because of the potential side-effects of ketosis, this diet must be prescribed and carefully monitored by a doctor, just as antiepileptic drugs are prescribed and carefully monitored.

About Antiepileptic Drug Therapy

The goal of drug therapy is always to prevent seizures with the lowest effective doses of antiepileptic medication and the least side effects. There are several important points to remember while you are taking antiepileptic medications.

Antiepileptic medications work best when there is a steady level of the drug in your body. The drug needs to reach and remain at the ideal level to be effective. With some medications, frequent blood tests are required to check the drug levels. Ask your doctor if the medication you are using needs to be monitored in this way — if yes, he or she will tell you where and when to have those blood tests done. Your medications might be adjusted based on the results. Remember to take your medication regularly as prescribed. If you miss a dose, don't double up. Resume your regular schedule and notify your doctor. If you stop taking your medicine abruptly, seizure activity will increase. If you miss more than one dose, or if you notice an increase in your seizures or if you develop a rash, call your doctor for instructions.

There are many medications — both prescription and over-the-counter — that can influence the effectiveness of antiepileptic medications. Be sure your doctor is aware of all the medications you take. Don't forget to mention vitamin and nutritional supplements, or herbal medications you may be using.

Ask your doctor about operating heavy equipment or having alcoholic drinks.

In the interest of protecting both the public and the driver, all states issue driving guidelines for people who have seizures. To protect yourself, ask your doctor about driving before you get behind the wheel, and follow the guidelines.

Do not change the dosage or stop taking your medicine without the approval of your doctor.

If one medication doesn't control your seizures, another drug or a combination of drugs may be prescribed.

Depending on the risk of seizure recurrence, you may need to continue taking antiepileptic medications for several months or years following your last seizure. This risk is determined on an individual basis by your neurologist. The decision is based on many factors including MRI scans, EEG (electroencephalogram) results, and the outcome of tumor treatments. The decision to taper off antiepileptic medication should be carefully planned by your doctor and you, and all appropriate precautions taken.

Sometimes antiepileptic drugs are prescribed as a precaution following brain surgery. Your doctor can tell you how long s/he expects you to use the medication "prophylactically."

Some of the medications for controlling seizures caused by brain tumors are:

- carbamazepine (Tegretol)
- divalproex sodium (Depakote)
- felbamate (Felbatol)
- gabapentin (Neurontin)
- lamotrigene (Lamictal)
- levetiracetam (Keppra)
- oxcarbazepine (Trileptal)
- phenobarbital (Luminal)
- phenytoin (Dilantin)
- tiagabine (Gabitril)
- topiramate (Topiramate)
- zonisamide (Zonegran)

Side-Effects of Drug Therapy

You will be given specific instructions for taking your medication. Your doctor or nurse will tell you the drug's common side-effects, which side-effects you should call the doctor about, and which side-effects should lessen with time.

Because most of the antiepileptic drugs can cause blood or organ disorders, your doctor will perform frequent physical exams and blood tests to avoid these potential effects.

Listed below are the most frequent side effects of the commonly used antiepileptic drugs. This

is not a complete listing, however. Information about your drug and the circumstances in which to call your doctor should be provided by your healthcare team. Most of the side effects below may be avoided through careful dose adjustments and by slowly increasing medications up to their target dose. Some people simply do not tolerate certain medications and need to be placed on other medications. Also, a "side" effect for one person may be a "welcome" effect for another — for example, Lamotrigene may cause insomnia in one person but cause increased alterness in another.

CARBAMAZEPINE (TEGRETOL)

Double or blurred vision, dizziness, drowsiness, nausea, headache, skin rash. This drug may decrease the effectiveness of oral contraceptives. Other drugs can cause the blood levels of Tegretol to increase or decrease.

DIVALPROEX SODIUM (DEPAKOTE) OR VALPROIC ACID (DEPAKENE)

Nausea, vomiting, indigestion, diarrhea, abdominal cramps which may lessen with continued use, drowsiness, anorexia or increased appetite with weight gain, temporary hair loss, photosensitivity. Do not break or crush the pills as they will irritate the mouth and throat. When used with Dilantin, Depakote may cause Dilantin levels to change.

FELBAMATE (FELBATOL)

Insomnia, weight loss, headache, nausea, sedation, dizziness. Use has been restricted by small but significant incidence of bone marrow suppression and liver toxicity. Because it is a highly effective agent which is usually nonsedating it is still used in difficult cases, but with careful blood monitoring.

GABAPENTIN (NEURONTIN)

Dizziness, drowsiness, fatigue, ataxia, sleepiness, nausea, vomiting, slurred speech, skin rash. Should not be taken within two hours of antacids.

LAMOTRIGENE (LAMICTAL)

Headache, nausea insomnia, vomiting, dizziness, double vision, and tremor. Rash may occur in 5% or more of patients usually within the first three months of starting the medication. The risk of rash is reduced by slowly increasing the lamotrigene dose. Lamotrigene blood levels will be reduced by phenytoin and carbamazepine and increased by valproic acid.

LEVETIRACETAM (KEPPRA)

Sedation, dizziness, headache, decreased appetite, nervousness. This medication is being used with increasing frequency in patients with brain tumors because of its lack of interaction with other medications and relatively good tolerability.

OXCARBAZEPINE (TRILEPTAL)

Double vision, impaired balance and coordination, dizziness, tremor, drowsiness, headache, and nausea. Chemically related to carbamazepine with probable similar efficacy. May cause reduction in blood sodium concentration.

PHENOBARBITAL (LUMINAL)

Lack of concentration, sleepiness, hyperactivity, depression, "hangover-like" headache, skin flushing, nausea, vomiting, skin rash. Commonly used for seizures in children. In adults, it may be used with Dilantin, or when other antiepileptic drugs are not effective. Several drugs can increase the effect of phenobarbital.

PHENYTOIN (DILANTIN)

Drowsiness, dizziness, low blood pressure, rapid jerky eye movements, clumsy walk, swollen gums, skin rash. Many drugs, prescription (including chemotherapy drugs) and over-the-counter (including aspirins and antacids), can increase or decrease the effectiveness of this drug.

TIAGABINE (GABITRIL)

Dizziness, fatigue, nervousness, tremor, impaired concentration, general weakness, depression.

TOPIRAMATE (TOPAMAX)

Impaired concentration, irritability, poor coordination, weight loss, fatigue, dizziness, word finding difficulty, increased risk of kidney stones. May change phenytoin levels.

ZONISAMIDE (ZONEGRAN)

Decreased appetite and weight loss dizziness, impaired coordination, sedation, fatigue, confusion and impaired concentration, and slightly increased risk of kidney stones.

NOTIFY YOUR DOCTOR IMMEDIATELY IF YOU:

- have any difficulty breathing
- run a temperature
- notice the whites of your eyes appear yellow
- have tiny purple spots on your skin
- become unusually confused
- have difficulty urinating
- bruise easily

Chest pain or inability to arouse someone taking antiepileptic drugs is always a medical emergency.

Managing Common Side Effects

The following hints may help you manage some common side effects of antiepileptic drugs.

DROWSINESS OR DIZZINESS

Do not operate equipment or machinery and don't drink alcoholic beverages. Use caution on stairways. Install grab bars in the shower and next to the toilet (these can be rented from a medical supply store). If the drowsiness persists, contact your doctor.

GUM SWELLING

This side effects occurs only with phenytoin (Dilantin). Good oral hygiene is a vital part of managing this side effect. If your gums are swollen, try using a mouth care "sponge" — they are available at most drug stores. A soft toothbrush is another option. Avoid mouthwashes containing alcohol as they will further burn and irritate your gums. Look for baking soda-based mouth rinses, or ask your dentist to suggest one. Be sure to tell your dentist about your medication — frequent professional cleanings may help limit gum swelling.

RASH

First, notify your doctor. A rash can indicate an allergic reaction to the drug, or may be due to an increased drug level. If itching accompanies the rash, a cool shower may help — it constricts the blood vessels in the outer layer of your skin. Pat skin dry instead of rubbing. Don't use lotions on the rash unless your doctor or nurse suggests it. Do not take additional doses of the medication that may be causing the rash until you have spoken with your doctor.

NAUSEA AND VOMITING

Be sure to take your medication with meals to decrease stomach irritation. If stomach upset continues, ask your doctor about antiemetic medication. Antiemetics block the messages to the vomiting center of the brain. Don't use over-the-counter antacids or aspirin-containing preparations for upset stomachs without first checking with your doctor. They may interfere with some antiepileptic drugs.

CONTINUED SEIZURES AND IDEAL DRUG LEVELS

Some seizures simply do not respond to a given drug. You may have to try another medication. Be sure to let your doctor know how often you have seizures, and if the side-effects of a particular drug interfere with your quality of life. Be aware that flu vaccines, as well as some prescription and non-prescription drugs, can increase seizure activity.

CONTINUED SEIZURES AND IRREGULAR DRUG LEVELS

Antiepileptics are frequently affected by other medications. If you are experiencing this problem, make a list of all your medications (over-the-counter as well as prescription drugs) and take it to your doctor or pharmacist.

Be sure to keep a record of your seizures, particularly the frequency and type. Discuss this with your doctor, and ask about other options for controlling your seizures.

For Additional Information

For more information about seizures and seizure medications, contact:

The Epilepsy Foundation
4351 Garden City Drive
Landover, Maryland 20785

Phone: 800-332-1000
Website: www.epilepsyfoundation.org

There is a small charge for some of their publications.

Chapter 8

Comfort & Coping

Whether you are the person with the tumor, a caregiver, or a family member, you might still be trying to make sense out of the words "brain tumor." You may be frightened or feeling isolated. Comfort and control probably seem like a dream.

This chapter offers suggestions and advice from professionals who specialize in helping people cope, and from other patients and those close to them who have had experiences similar to yours. We hope some of their ideas work for you.

What Are Seizures?

A seizure is an attack caused by abnormal electrical activity in the brain. It lasts only a short period of time and may cause unusual movements, a change in the level or loss of consciousness, and/or sensory distortions. Epilepsy is defined as recurrent seizures.

Normally, your body's nerve cells communicate with each other via carefully controlled electric signals. If something interferes with those signals and they become more intense, a seizure results. While seizures are usually brief, their effects may linger for several hours.

There are different types of seizures. The type you experience depends on which area of the brain has the abnormal electrical signals.

Most seizures occur randomly, at any time and without any particular cause. However, you might have some advance notice. Headache, mood changes and/or muscle jerking might signal a coming seizure. Those warning signals are called "auras." An aura may precede a seizure by a few seconds or even minutes. Use that time to safeguard yourself. For example, if you are chewing, remove the food from your mouth. If you are walking, sit or lie down.

If you have recurrent seizures, you might notice that some events "trigger" them. Bright lights, flashing lights, specific odors, lack of sleep, missed meals, menses, increased stress or emotional difficulties, alcohol, new medications, or changed dosages of existing medications can all be triggers. Keeping track of what you were doing immediately prior to each seizure can help you identify your personal triggers. Having a seizure does not necessarily mean your tumor is growing.

Types of Seizures

There are two primary types of seizures — partial (also called focal) seizures and generalized seizures.

PARTIAL (FOCAL) SEIZURES

There are two types of partial seizures: Simple partial seizures, which don't cause unconsciousness and complex partial seizures, which do cause loss of consciousness.

Simple partial seizures
Simple partial seizures commonly cause convulsive jerking or twitching (if the frontal lobe is involved), tingling or numbness (if the parietal lobe is involved) or other unusual sensations. These symptoms can begin in one part of the body and then spread to other areas. Chewing movements or lip smacking (if the anterior temporal lobe is involved), buzzing in the ears, flashes of lights, sweating, flushing and pupil dilation are other common symptoms. Psychic symptoms include a sense of déjà vu, imaginary sights (if the occipital lobe is involved), smells (if the temporal lobe is involved) or tastes, or imaginary sounds.

Complex partial seizures
Complex partial seizures cause some loss of consciousness and usually indicate temporal lobe involvement. Purposeless, automatic movements might occur. The seizure may be preceded, accompanied by, or followed by psychic symptoms. A state of confusion may last for a time after the attack. In patients with low-grade gliomas, this is the most common type of seizure.

GENERALIZED SEIZURES

These seizures may begin as partial seizures and abruptly change into generalized seizures. There are several different types of generalized seizures.

Absence (petit mal) seizures
Absence seizures cause an impairment of consciousness and may be accompanied by a feeling of limpness. The person having the seizure may miss a few words or stop speaking for a few seconds during a conversation. You may think he or she has been daydreaming. The beginning and end of the episode is usually sudden. This type of seizure most commonly begins in childhood and often stops by age 20.

Atypical absence seizures
Atypical absence seizures may cause more extensive changes in muscle tone, or they may have a more gradual beginning and ending than typical absence seizures.

Atonic seizures (epileptic drop attacks)
Atonic seizures, also called "epileptic drop attacks," are characterized by sudden limpness. Generally, all muscle tone and consciousness are lost.

There are many books available that can help parents explain their illness to children. Although most of these books are about cancer, the advice they contain is useful for many illnesses. Read these books with your children; offer them the opportunity to ask questions and to express their fears and concerns.

Most importantly, remember that children of all ages need to be reassured that you have planned for their needs. Explain those plans and arrangements to your children, making sure they know you are still very much involved, even if from a distance.

If friends offer to help, accept their offers. You will benefit from the assistance, and your friends will feel needed. Groceries, laundry, a meal on the day of your doctor visit, transportation to the clinic for therapy — there are many possibilities. Keep a "Wish List" of things you "wish" you had the time to do. When someone offers to help, reach for that list. Don't be shy!

Although most people will be supportive, some will be unable to deal with or even acknowledge your illness. Also, be prepared for well-meaning neighbors who insist upon telling you stories about "miraculous" cures. Don't let their second and third-hand news make you feel obligated to start yet another information search. Thank them for their concern, but remember to put their tales in perspective. There are many different types of brain tumors, and many different treatments. What works for one person may not be appropriate for another. Ask your doctor.

Your Feelings

When you first heard your diagnosis, you were probably shocked. Chances are you understood or remember little of what you were told at that time. That is a perfectly normal reaction. Most people experience some or all of the following coping mechanisms following the diagnosis of a brain tumor.

DENIAL

Denial — disbelief or lack of concern over the diagnosis — is normal for some. It may take time to accept the news. Some may initially pretend it hasn't happened. Others may be in a state of shock. "How could I have a brain tumor?" or "Why me?" are common questions. Some people may refuse to discuss or even acknowledge their diagnosis.

GUILT

When something overwhelming happens, people try to blame someone. When you blame yourself, you feel guilt. People ask: Is this a punishment? Did I do something to deserve this? The cause of most brain tumors is unknown. Nothing you did, said or thought made this happen.

ANGER

Anger at your husband, wife, children, neighbor, boss, doctor or anyone and everyone — is not unusual. You may say hurting, bitter things you don't really mean and later regret. Small children may kick or bite to show their anger. Hidden anger sometimes causes irritability, sleeplessness, fatigue, over-eating, or over-drinking.

DEPRESSION

Depression or grief at the loss of your previous lifestyle may occur. While physical activity may be the last thing you feel you have the energy for at this time, it often helps the most.

Later, or when you complete treatment and your life becomes less hectic, the enormity of all that is happening becomes vivid. Now, you need to cope with your fears and anxiety.

It is normal for people to experience anxiety when going through stressful times. Many people feel "anxious" while waiting for test results or when returning to the doctor for follow-up visits. Symptoms of anxiety include a sense of fear, a feeling that "something bad" is going to happen, a rapid heart rate, perspiration, nausea, shortness of breath, dizziness, or a feeling of unreality.

It is important to talk to your doctor about your physical symptoms even though they may be psychologically based. Sometimes, just the reassurance that your doctor provides will be enough to relieve your anxiety. If your doctor determines that the symptoms warrant treatment, he may suggest medication or an appointment with a psychiatrist, psychologist or social worker.

While many of the feelings people experience are normal and can be worked through, there are some for whom these changes are overwhelming. Those people may become very depressed, and need help in dealing with those feelings. Some of the symptoms of major depression are: persistent depression or no feelings whatsoever; irritability; loss of enjoyment and pleasure in people or activities that are normally enjoyable; difficulty sleeping — such as trouble falling asleep or waking too early and being unable to fall asleep again; loss of appetite; or wanting to give up or to inflict self-harm. When these feelings persist for more than two weeks, or when they are severe, it is important to bring the symptoms to the attention of a doctor. The doctor will determine whether these are signs of major depression, and if so, will provide direction. The doctor may prescribe medication or suggest a psychiatric consultation. Depression is treatable, but first must be diagnosed.

There is no magic pattern for dealing with your emotions. One day you may feel better, and the next day feel upset again. Not everyone shows their emotions, nor does everyone have the same kinds of feelings. If this is your first experience with crisis, you will learn which coping methods work best for you. Hopefully, those who deal with their emotions in an unpressured way will begin to accept the reshaping of their lives, facing it with a realistic amount of hope and a determined attitude.

Living Your Life

Part of our identity is how we present ourselves to others. An undesired change in the way we look can understandably be upsetting.

Hair lost during surgery, radiation, or chemotherapy often grows back, but may take months. Wigs are available for both men and women. If you find a wig uncomfortable, consider a scarf or a loose hat.

Look through your closet for the clothes you look best in. Or, treat yourself to a new blouse or tie. When you look good, you feel better. Many hospitals offer make-up and hair sessions for those who have gone through cancer treatments. The workshops give you tips about your appearance, and are great for your self-confidence.

Many people with a brain tumor have questions about sex. Can I still have sex? How soon after surgery can I have sex? Will my treatments affect my desire for sex? Talk to a member of your healthcare team — they can answer your questions and provide suggestions.

Your desire for sex may decrease temporarily because you're tired, you feel unattractive, or you fear hurting yourself. Or, your partner may be afraid of hurting you. For the time being consider replacing sexual activity with non-sexual physical closeness such as holding hands, kissing or hugging. Find activities you can comfortably share and special times to be alone.

You may feel tired due to medications, treatments, and traveling to and from your treatments. Be realistic — keeping up with your usual responsibilities may be difficult. Set priorities. Do only what has to be done, and if you still have the energy or inclination, then consider other chores or errands. Call upon friends and neighbors to help. Plan frequent rest periods during the day. Save your energy for special events or unavoidable chores.

Make time to be good to yourself. Take up a hobby or learn a new craft. Visit your hair dresser. Go to the library and check out those books you always wanted to read. Keep a journal, take a walk, pray or laugh. Look for ways to enjoy yourself.

Coping With Stress

For most people, a fear of the unknown and an uncertain future cause great stress. This is normal. Give yourself permission to be temporarily overwhelmed. Then, take a deep breath and begin to think about the things you can control.

Ask family and friends to help with household responsibilities. Find someone to assist you in completing medical forms and claims. Participate in planning your treatment. Help determine your medication or treatment schedules. Decide which chores are important, and which can be temporarily ignored. Choose to share your experience with others, or not. The choice is yours.

Reducing stress means being kind to yourself. Soft music, attending a ball game, a mid-afternoon nap — all are relaxing activities that also pamper you.

If you are a family member or a caregiver, permit yourself some "time off" to take care of your own needs, despite the confusion of the situation. Call upon other relatives or friends to serve as relief workers so you can take much needed breaks.

Communication is an important part of reducing stress. Talk to your family about your needs, feelings, and responsibilities. Listen to their concerns as well. Sometimes one person will take on too many responsibilities. Or, in trying to protect others, a family member may not express her/his own needs. Taking the time to talk — about what needs to be done and who can reasonably do it — allows everyone to feel useful and avoids feelings of resentment. Relaxation, meditation or imagery techniques can also help reduce stress for you and your family. Consider taking a class together.

Birthdays, holidays, or anniversaries can be a difficult time for your family. Anxiousness or irritability around these days is normal. Plan ahead and make activities simple and memorable.

Close friends, religious leaders, or your health professional can be a source of emotional and physical strength. Friends may be able to search for community and medical resources of value to you. Contact your library, local civic organizations, village hall, or religious institutions. Many community programs are available — learn what they are and take advantage of their services. Each resource you find makes it easier for you and your family to cope with your new situation.

Finding a Support Group

Most of us don't want to be alone when facing a crisis. Emotional support from family, friends, and loved ones gives us comfort and strength, but may not be enough. There is often a need to connect with someone in the same situation.

Patients and families often find help through brain tumor support groups. A support group is a gathering of people seeking to share their experiences with a professional. They come for emotional, and possibly, spiritual support. Within the safety of a support group, many people are able to share their fears and concerns about day-to-day problems and the future.

There are different types of support groups for adults, for parents of children with brain tumors, for children and siblings. Most of these groups also welcome concerned friends. If you are not comfortable with a particular group or it doesn't meet your needs, try another one.

SOCIAL WORK SERVICES

Our social workers can help you or your family explore other support options as well. There are many sources of online support, community-based wellness programs, and opportunities to contact others living with this diagnosis. Our Social Work office can be reached at 800-886-2282.

Chapter 9

Questions to Ask

Whether you are just beginning treatment, are a long term survivor, or somewhere in between, you probably have some unasked or unanswered questions. You might be concerned about your symptoms or want to ask about treatment options. You may have obtained copies of your medical records and read something you don't understand. Or perhaps you would like guidance about resuming your routine activities.

We encourage you to take these questions to your health-care team. Your doctors and nurses can respond with personalized answers which cannot — and often should not — be provided by outside sources. By asking questions you're participating in your healthcare. By gathering information, you'll feel more comfortable making decisions about your treatment plan.

In this chapter, we offer some sample questions you may want to ask at various times during your illness. Feel free to modify this list based on your particular concerns and situation.

Talking to Your Healthcare Team

Make a list of your questions and bring them with you when you visit your doctor. Be sure the questions that concern you the most are at the top of the list. If you think of other questions after you return home, begin a list for the next visit.

If you want to bring family or friends with you when you visit your doctor, make an appointment for a conference. Let the receptionist know the purpose of your visit — that way, a block of time can be set aside for you.

Your First Visit

Many people don't remember much when their doctor first tells them they have a serious disease. Try to come away with some basic information:

- Where is the tumor located?
- Based on the scans, do you have an idea of the type of tumor?
- What is the next step? Do I need more tests? Do I need to see any specialists?
- Until we know more, should I continue my daily routine? Can I work? Should I drive?
- Do I need to take any medication? If so, what is it for? What are the side-effects?

About Insurance

After your first visit, you'll need to verify your healthcare insurance coverage. The answers to most of your insurance questions can be found in the insurance policy itself or the policy manual. If you don't have a copy, now is the time to obtain one.

For employer-provided health insurance, contact your employer's Human Resources office or your benefits manager and ask for the manual. For individual policies, call your insurance agent. For Medicare/Medicaid coverage, call the Medicare Hotline at 800-633-4227. For CHIP coverage (Comprehensive Health Insurance Programs) through your state, call your state Department of Insurance.

If you are uninsured, please begin by contacting the social worker at the hospital at which you will be treated. You can reach the social work department by calling the general hospital number and asking for the social work office. The social worker can outline federal assistance programs, local and national funding organizations, and ways to help you obtain alternate forms of healthcare coverage.

QUESTIONS FOR YOUR INSURANCE PROVIDER

Be sure you know the answers to these questions:

- Do you need to obtain pre-certification for hospitalization or treatment? If so, who do you call? Most insurers include the pre-certification telephone number on the back of the insurance card. When you call, be sure to record the name of the person you speak with, the date, and the "case number" assigned to your claim.
- Do you need to obtain a second opinion before non-emergency surgery? If so, are there any limitations on who provides the second opinion?
- Do you need to stay within a particular network of hospitals or physicians to receive your benefits? Do you have a current list of those providers? What will happen if you are treated "outside the network?"
- Does your policy have a deductible? If so, how much of that deductible have you paid for the year? Knowing this will help avoid "surprise" bills for which you are responsible.
- Will your insurance cover investigational treatment if you choose it?

Seeing a Specialist

One of your next visits will likely be to a specialist. Regardless of whether the next step is a consultation regarding surgery, radiation, chemotherapy or another treatment, the basic questions are very much the same.

QUESTIONS FOR A SPECIALIST

You'll want to know:

- What treatment is recommended?
- What is the goal of that treatment? To cure the tumor, to control the tumor, or to control symptoms?
- What are the potential benefits of the treatment?
- What are the risks and side-effects of the treatment?
- What will happen if I don't have this treatment, or if I postpone it?
- Are there other options beside this treatment?
- Is this an experimental treatment?
- Will I need any more tests before the treatment begins?
- How will we know if the treatment was effective?
- What type of follow-up will I need, and when?

Following Treatment… A Next Step

Eventually, the frequent appointments for therapy stop, and the dates for follow-up care become further apart. The pace slows, and another period of adjustment begins. Now is the time to begin re-defining "normal" in your life. It's a time to slow down and be good to yourself.

QUESTIONS FOLLOWING TREATMENT

When you finish your last treatment, be sure you know:

- When is my next doctor visit? Which doctor(s) do I see, and how often?
- When is my next scan? Do I need a doctor's order? How will it be scheduled?
- Do I need any medications? If so, are there any potential side-effects?
- Can I work? If so, do I have any restrictions on my activities? Will I need any work site accommodations?
- Can I drive?
- Can I exercise? If so, do I have any limitations?
- What type of diet should I follow? Is there a registered dietician I can consult to provide me with healthful eating guidelines?

Living with a Brain Tumor

As time goes on, you and your family may have questions about concerns common to all people living with a brain tumor — patients and family members alike. Those concerns may involve:

- financial assitance
- employment interests
- vocational re-training
- obtaining new health insurance
- sexuality
- forming new relationships
- starting or adding to your family
- parenting
- counseling or support groups
- rehabilitative services
- cosmetic and image interests

As more brain tumor patients become survivors, there are increasing resources for people living with a brain tumor. Tap into these services and learn how they can help enrich your life. Our social work program can help you explore these, and other, opportunities. Please feel free to call us at 800-886-2282.

Notes

Notes

Notes

Publications & Services

BUILDING KNOWLEDGE

A Brain Tumor — Sharing Hope
Tumor del Cerebro — Compartiendo la Esperanza
Dictionary for Brain Tumor Patients
Living with a Brain Tumor
A Primer of Brain Tumors

FOCUSING ON TUMORS

Ependymoma
Glioblastoma Multiforme and Anaplastic Astrocytoma
Medulloblastoma
Meningioma
Metastatic Brain Tumors
Oligodendroglioma and Oligoastrocytoma
Pituitary Tumors

FOCUSING ON TREATMENT

Chemotherapy
Radiation Therapy: A Basic Guide
Stereotactic Radiosurgery
Steroids
Surgery
Physician Resource List: Physicians Offering Clinical Trials for Brain Tumors

FOR & ABOUT CHILDREN

Alex's Journey: The Story of a Child with a Brain Tumor *(Video or Booklet)*
When Your Child Returns to School

SUPPORT RESOURCES

Bibliography
Care Options
Emergency Alert Wallet Cards
Employment Information
End-of-Life Care
Financial Aid Resources
Health Insurance Resources
Housing During Treatment Resources
Net-Working Links
Scholarship & Educational Financial Aid Resources
Social Security Disability Resources
Spanish-Language Resources
Transportation Assistance Resources
Wig and Head Covering Resources
Wish Fulfillment Resources

NEWSLETTER

Message*line* Newsletter
Sharing Knowledge, Sharing Hope e-News

FOCUSING ON SUPPORT

Connections — A Pen Pal Program: Information
Listing of Brain Tumor Support Groups
Listing of Bereavement (Grief) Support Groups
Organizing and Facilitating Support Groups
Resources for Online Support
TLC (Tips for Living and Coping) e-bulletin

Single copies of these publications are available free of charge.

American Brain Tumor Association
2720 River Road, Suite 146 Des Plaines, Illinois 60018
800.886.2282 TEL info@abta.org EMAIL
847.827.9918 FAX www.abta.org WEB

Sharing knowledge. Sharing hope.

American Brain Tumor Association

2720 River Road, Suite 146 Des Plaines, Illinois 60018

800.886.2282 TEL info@abta.org EMAIL
847.827.9918 FAX www.abta.org WEB