Chapter 6

Types of Brain and Spinal Cord Tumors

This chapter contains, in alphabetical order, information about the more common brain and spinal cord tumors, their typical symptoms and locations, and how they might be treated. Please remember that your tumor is unique and might not conform to the "average" characteristics described.

The tumor names we use are based on the WHO (World Health Organization) brain tumor classification system.

In addition to the tumor and treatment information in this chapter, we also offer two other resources — our *Focusing on Tumors* and *Focusing on Treatment* series of publications. The *Focusing on Tumors* booklets contain detailed information about the most common types of brain tumors: meningioma, glioblastoma and malignant astrocytoma, oligodendroglioma and oglioastrocytoma, metastatic brain tumors, pituitary tumors, medulloblastoma, and ependymoma. The *Focusing on Treatment* booklets explain various types of surgery, radiation therapy, sterotactic radiosurgery, and chemotherapy. Visit our website at www.abta.org to access those resources, or call us at 800-886-2282.

Acoustic Neuroma

Also called Neurilemmoma, Vestibular Schwannoma or Neurinoma

The acoustic neuroma is a benign tumor of the nerve of hearing (the 8th cranial nerve). It is located in the angle between the cerebellum and the pons, in the posterior fossa (the back of the skull). This tumor usually grows very slowly.

CROSS SECTION OF THE EAR

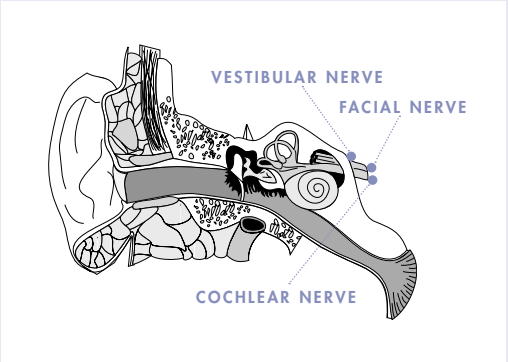

Acoustic neuromas typically occur in adults, particularly in their middle years. Females are twice as likely to have this tumor as males. Acoustic neuromas account for fewer than 7.5% of all primary brain tumors.

Common symptoms are one-sided hearing loss and buzzing or ringing in the ear. Dizziness may also occur, but is less common. If the tumor also affects the facial nerve (the 7th cranial nerve) located next to the 8th nerve, facial paralysis can occur. Other symptoms include difficulty in swallowing, impaired eye movement, taste disturbances, and unsteadiness.

Total removal using microsurgical techniques is often possible. Stereotactic radiosurgery might be used as an alternate to surgery for some patients.

Tumors on both sides (bilateral) are rare, and tend to be familial. They are almost always associated with *neurofibromatosis 2*, a hereditary condition. The malignant form of this tumor, *malignant peripheral nerve sheath tumor* (MPNST), is extremely rare.

For more information on acoustic neuromas, contact:

Acoustic Neuoma Association
600 Peachtree Parkway, Suite 108
Cummings, Georgia 30041

Phone: 770-205-8211
E-mail: ANAUSA@aol.com
Website: www.ANAUSA.org

Astrocytoma

Astrocytomas are tumors that arise from astrocytes — cells that make up the "glue-like" or supportive tissue of the brain. The cells are named for their star-like shape. These tumors are "graded" by the pathologist to indicate how normal, or how abnormal, the cells of the tumor look. Grade I astrocytomas have slightly unusual looking cells; the cells of a grade IV astrocytoma are very abnormal in appearance. In this section we'll describe the various grades of these tumors. The list begins with grade I tumors and progresses through grade IV astrocytomas.

Sometimes, terms describing the location or the appearance of an astrocytoma may be attached to its name. For example, a butterfly glioma is a high grade astrocytoma that has spread through both sides of the brain, causing a "butterfly" appearance on scans. A cerebellar astrocytoma is an astrocytoma found in the cerebellum of the brain.

ASTROCYTE

Astrocytes are the cells that make up the "glue-like" or supportive tissue of the brain.

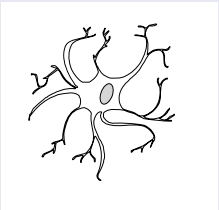

CEREBELLAR ASTROCYTOMA

"Cerebellar astrocytomas" are astrocytomas found in the cerebellum — the lower, back part of the brain which controls balance. More than 80% of cerebellar astrocytomas are grade I, localized, cystic (fluid-filled) tumors although higher grades of tumor do occur. Malignant cerebellar astrocytomas and spread

THE CEREBELLUM

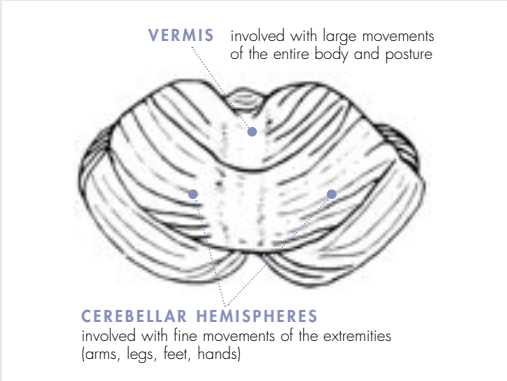

of this type of tumor are rare. The cerebellar location is more common in children than adults and is usually very accessible to the neurosurgeon.

Surgery is the primary treatment and if "total" removal is possible — meaning that all tumor visible to the surgeon's eye is able to be removed — additional therapy might not be needed. In adults and older children, radiation might be recommended for an incompletely removed or a higher-grade tumor. Further treatment might be needed only if the tumor recurs. For children under three, chemotherapy may be used to delay the use of radiation therapy until the brain has further matured.

If the tumor recurs, a second surgery, radiation, or chemotherapy can be considered.

DESMOPLASTIC INFANTILE ASTROCYTOMA (DIA)

DIAs are very rare grade I astrocytomas. These large, cystic tumors are usually diagnosed in infants under the age of two, although in some circumstances they have been seen in older children and young adults. They tend to arise in the supratentorium — the area above the membrane that separates the cerebral hemispheres from the posterior fossa of the brain. It is not uncommon for these tumors to grow quite large and spread through more than one lobe of the brain. Symptoms usually include an increase in the size of the baby's head, hard and bulging fontanelles (the "soft spots" of the infant's skull), and eyes that focus downward. Seizures, hyperactive reflexes, and a palsy of the sixth and seventh nerves may also be seen. Skull xrays may show changes in the bone near the tumor, and a large mass is commonly seen on MRI. Despite the size of these tumors and the young patient age, surgical removal of all visible tumor often results in long term tumor control.

PILOCYTIC ASTROCYTOMA

Also called Juvenile Pilocytic Astrocytoma

These grade I astrocytomas are usually non-infiltrating tumors, meaning they tend to stay in the area in which they started and do not spread into surrounding tissue. They generally form cysts, or may be enclosed within a cyst. Although these are usually slow growing tumors, they can become very large.

Pilocytic astrocytomas are the most common glioma in children. They are generally diagnosed in children and young adults under the age of 20, and are rarely seen in older adults. They are the most benign tumor of the astrocytomas. Many optic gliomas and cerebellar astrocytomas are pilocytic astrocytomas.

Pilocytic astrocytomas are generally considered benign tumors and are often cured by surgery alone. In adults and older children, radiation therapy might follow surgery if the tumor cannot be completely removed, or the residual tumor may be carefully watched. In a "watchful waiting" situation follow-up MRI scans are done at regular intervals to monitor for possible re-growth. If the tumor recurs, re-operation and some form of radiation are options. Some pilocytic tumors, such as most optic gliomas, cannot be safely removed because of their location and initial treatment may involve observation only.

The term "anaplastic" or "malignant" pilocytic astrocytoma is used only when the tumor has developed an extensive blood supply around the tumor, or the tumor contains dead cells called necrosis. These rare tumors require more aggressive treatment than a benign pilocytic astrocytoma

SUBEPENDYMAL GIANT CELL ASTROCYTOMA

Subependymal giant cell astrocytomas are ventricular tumors associated with tuberous sclerosis. *Please see the section on tuberous sclerosis for additional information.*

DIFFUSE ASTROCYTOMA

Also called Astrocytoma, Low Grade or Astrocytoma Grade II (types: Fibrillary, Gemistocytic, Protoplasmic Astrocytoma)

These low grade astrocytomas tend to be infiltrating tumors, capable of growing into surrounding tissue, but tumors which grow relatively slowly.

These astrocytomas are grouped by the appearance and behavior of the cells for which they are named. For example, the nuclei of fibrillary astrocytoma cells are cigar-shaped; this type of astrocytoma tends to contain microcysts and mucous-like fluid. Protoplasmic astrocytoma nuclei are round or oval in shape. These tumors also tend to contain microcysts and mucous-like fluid. Gemistocytic astrocytomas are plump, glassy, angular shaped cells. (Until recently there had been some disagreement as to the grade of the gemistocytic astrocytoma. Some pathologists considered this to be a grade III tumor since the gemistocytic astrocytoma, in particular, tends to recur as an anaplastic astrocytoma. The WHO classification system published in 2000 defines these as grade II tumors.)

Regardless of the cellular appearance of these grade II astrocytomas, surgical removal may be suggested for accessible tumors (tumors that may be removed without causing undue neurological damage). If "total" surgical removal can be achieved, periodic follow-up with MRI or CT scans might be the only additional care required. It is important to realize that "total" removal generally means removal of all of the tumor visible to the neurosurgeon's eye. Microscopic cells, too small to see, can remain behind or may have spread to nearby tissue. Those cells may later begin to re-grow. However, even with incomplete removal these tumors tend to grow very slowly, and it may be several years before symptoms reappear due to tumor re-growth.

In adults and older children, radiation therapy may be suggested in addition to surgery, or radiation may be used to treat a low grade astrocytoma which is unable to be removed. The role of chemotherapy in treating these tumors is under investigation. Further treatment might be recommended only if the tumor recurs. Children younger than three might receive chemotherapy so that radiation can be delayed.

These low grade tumors may recur as a higher grade tumor; thus, periodic follow-up and attention to the return of symptoms is important. Treatment of the recurrent tumor would be based on the tumor's grade at the time of re-growth.

ANAPLASTIC ASTROCYTOMA

Also called Malignant Astrocytoma or Grade III Astrocytoma

An anaplastic astrocytoma is a grade III tumor. Astrocytomas often contain a mix of cells and cell grades, but brain tumors are graded by the highest grade (most abnormal) cell seen in the tumor. These tumors tend to have tentacle-like projections that grow into surrounding tissue, making them difficult to completely remove during surgery. The word "anaplastic" means malignant, and because of this, treatment for an anaplastic astrocytoma may be more aggressive than treatment for a lower grade tumor.

The treatment options your doctor outlines will be based on the size and location of the tumor, what it looked like under the microscope, if and how far the tumor has spread, any previous treatment, and your general health. Generally, the first step in the treatment of anaplastic astrocytomas is surgery. The goals of surgery are to obtain tumor tissue for diagnosis and treatment planning, to remove as much tumor as possible, and to reduce the symptoms caused by the presence of the tumor. There are some circumstances, such as certain medical conditions or concerns about the location of the tumor, in which a biopsy may be done in place of surgery. The tissue obtained during the biopsy is then used to confirm the diagnosis.

Because the tentacle-like cells of an astrocytoma grow into the surrounding tissue, these tumors cannot be totally removed during surgery. Partial removal can help decrease symptoms; the tissue obtained during that surgery confirms the type of tumor. Radiation is then used to treat the remaining tumor. There are several forms of radiation therapy available — conventional external beam radiation, focused radiation or stereotactic radiosurgery, implanted radiation, or conformal radiation. Your radiation oncologist will determine which is best for your particular tumor.

Some treatment plans include the use of chemotherapy for anaplastic astrocytoma. BCNU, CCNU, procarbazine, cisplatin, and temozolomide are commonly used drugs. Some clinicians recommend the use of chemotherapy prior to radiation; in these circumstances the chemotherapy may reduce the amount of tumor to be treated, and may serve as a radiation sensitizer. Other treatment plans may call for the implantation of biodegradable wafers containing BCNU into the cavity created during tumor removal. Still other physicians choose not to use chemotherapy for the initial tumor, "reserving" it for re-growth if necessary.

Anaplastic astrocytomas tend to recur, and when they do, they may regrow as a higher grade tumor. Treatment is based on the grade of tumor at recurrence.

We offer additional information specifically about anaplastic astrocytoma and glioblastoma multiforme, a grade IV astrocytoma. Please call our office if you would like that information.

ASTROCYTOMA GRADE IV

Also called Glioblastoma Multiforme

"Grade IV astrocytoma," "glioblastoma," "glioblastoma multiforme," and "GBM" are all names for the same tumor. Glioblastomas arise from astrocytes — star-shaped cells which form the supportive, glue-like substance of the brain. These tumors represent about 20% of all primary brain tumors and about 50% of astrocytomas. They are more common in older adults, and affect more men than women. Only nine percent of childhood brain tumors are glioblastomas.

Glioblastomas are generally found in the cerebral hemispheres of the brain, but technically can be found anywhere in the brain or spinal cord. Because the glioblastoma is capable of very rapid growth, the first symptoms are usually due to increased pressure in the brain. Headaches, seizures, memory loss, and changes in behavior are the most common presenting symptoms.

Glioblastomas commonly contain a mix of cell types. It is not unusual for the tumor to contain cystic material, calcium deposits, blood vessels, or a mixed grade of cells. Brain tumors, however, are graded based on the most malignant cell found in the tumor, and any astrocytoma that contains necrotic (dead) cells and an extensive network of blood vessels is generally a glioblastoma. The lack of uniformity from end to end of the tumor makes a glioblastoma one of the most difficult brain tumors to treat. While one cell type may be responsive to treatment, other types may be resistant.

The first step in treating a glioblastoma is surgery to remove as much tumor as possible. Radiation therapy almost always follows surgery or biopsy. There are several different forms of radiation therapy — ranging from conventional external beam radiation to stereotactic radiosurgery to conformal radiation therapy — which might be suggested. Other types of radiation therapy, such as implanted liquid radiation or monoclonal antibodies tagged with radioactive particles, may also be considered.

Chemotherapy might be given before, during or after radiation. The most commonly used drugs for adults are BCNU, CCNU, procarbazine, or temozolomide. Biodegradable wafers containing BCNU may be placed in the cavity created by tumor removal. Other new delivery systems are under investigation. Chemotherapy might also be used in children under the age of three to delay radiation.

Antisense therapies block the messages given off by malignant cells, altering their ability to interfere with the normal growth of surrounding cells. Protease inhibitors, such as marimastat and tamoxifen, block the ability of tumor cells to make the proteins needed for tumor cell reproduction. Angiogenesis inhibitors may be capable of interrupting the blood supply to a tumor, thus controlling tumor growth.

Immunotherapy is the use of the body's own immune system to fight a tumor. There are several research studies focusing on this area of treatment, and many of the programs are open to those with a glioblastoma. Immunotoxins, such as diptheria or pseudomonas, link a toxin to an antibody and carry it to the tumor cells. Interferons are thought to inhibit tumor cell growth by stimulating the immune system; they may also be angiogenesis inhibitors. Other researchers are using gene therapies as a way of controlling tumor growth. In one

method, specially-engineered genes make tumor cells more susceptible to drug therapy. In another method, gene therapy is used to stimulate the body's natural production of immune substances. Gene therapy may also be used to restore the normal function of tumor suppressing genes within tumor cells.

New drugs, new drug combinations, and new ways of delivering those drugs are being studied; these treatments are offered in organized research programs called clinical trials. Many clinical trials are available for glioblastoma — both as initial treatment and as treatment for a recurrent tumor. Many of those clinical trials can be found through the Cancer Information Service at 800-422-6237.

Recurrent tumors can be treated with additional surgery, another form of focused radiation, chemotherapy, or any number of experimental approaches as mentioned above.

Additional information about glioblastoma appears on page 37.

Atypical Teratoid Rhabdoid Tumor (ATRT)

This rare, high grade tumor occurs most commonly in children younger than two years of age. It is generally found in the cerebellum — the lower, back part of the brain which controls balance. These tumors tend to be aggressive and frequently metastasize through the central nervous system. Previously thought to be PNETs (primitive neuroectodermal tumors) or medulloblastoma tumors, ATRTs were recently found to have their own histologic and cytologic features which help a pathologist specifically define this tumor. Treatment generally involves removal of the tumor followed by chemotherapy. Radiation therapy may be considered depending on the age of the child, and whether the tumor has recurred. Clinical trials are underway to help develop chemotherapy drugs effective against this tumor — those clinical trials can be found by calling the Cancer Information Service at 800-422-6237.

Chondroma

This rare, benign tumor tends to arise at the base of the skull, especially in the area near the pituitary gland. A chondroma is generally very slow growing and might be present for a long time before causing any symptoms.

These tumors are composed of cartilage-like cells and are usually attached to the dura mater, the outermost layer of the meninges. A chondroma can grow to a large size, and may occur as a single or as multiple tumors. The malignant form of this tumor is called a chondrosarcoma (see the chondrosarcoma section which follows).

Because it is usually accessible with well-defined margins, surgery might be the only treatment required for a chondroma.

Chondrosarcoma

This very rare tumor arises from bone and is composed of cartilage. It is the malignant variant of the benign chondroma (described above) and tends to spread locally, staying within the same general area. This tumor is generally slow growing and rarely metastasizes, or spreads, to areas farther away. It is most commonly found in the sphenoid bone — the bony ridge running along the back of the eyes — or near the clivus, a bony area at the base of the skull. The chondrosarcoma is more common in adult males.

Standard treatment is surgical removal which might be followed with radiation therapy. Those with a chondrosarcoma may also be eligible for treatment in a clinical trial — an organized research study. Those studies can be found through the Cancer Information Service at 800-422-6237.

Chordoma

The chordoma occurs at the base of the skull in about one-third of patients, or at the end of the spine. It is a benign, slow growing tumor. When found in the spine these tend to be extradural tumors, meaning that they are located on the outside of the spinal cord. However, a chordoma may invade the nearby bone, compressing parts of the brain in the

area. It is not unusual for a chordoma to push into the brainstem or grow into the sinuses. Distant spread is rare. This is an uncommon tumor representing only 0.2% of all primary CNS tumors. Although it is found in people of all ages, chordomas are most frequent in younger and middle-aged adults. The most common symptoms are double vision and headache.

The chordoma is visible on CT and MRI scans, but a biopsy is necessary to determine an exact diagnosis. The skull base location can be very difficult to access, making complete removal of tumors in this area a challenge. A combination of surgery followed by radiation is the standard treatment for tumors located in the skull base. Stereotactic radiosurgery and stereotactic radiotherapy have shown promise, as has the combination of aggressive surgery followed by combined proton-photon beam therapy. Complete surgical resection of visible tumor might be possible for the spinal chordoma.

Choroid Plexus Carcinoma

This tumor, which occurs primarily in children, is the malignant form of the choroid plexus papilloma. It comprises about ten percent of all choroid plexus tumors and typically occurs in one of the lateral ventricles. (The choroid plexus carcinoma is sometimes called an anaplastic choroid plexus papilloma.) These tumors commonly invade, or grow into, nearby tissue and spread widely via the cerebrospinal fluid. Hydrocephalus — a collection of cerebrospinal fluid within the brain — is often present.

Treatment often includes surgery, chemotherapy and radiation therapy. A second surgery might be recommended for recurrent tumors, followed by some form of radiation and/or chemotherapy.

Choroid Plexus Papilloma

The choroid plexus papilloma is a rare, benign tumor most common in children under the age of two. About 3% of the primary brain tumors in children are choroid plexus papillomas. They represent fewer than 1% of all primary brain tumors. The choroid plexus carcinoma is the malignant form of this tumor.

In very young children, the lateral ventricles are the most common location of this tumor. The fourth ventricle is the most common site in adults. Both CT and MRI scans detect these tumors.

The choroid plexus papilloma grows slowly within the ventricles. It eventually blocks the flow of cerebrospinal fluid, causing hydrocephalus and increased intracranial pressure. Headache and other symptoms of increased pressure are common.

The standard treatment is surgery and may be the only treatment required if the tumor is completely removed. Tumor removal relieves the hydrocephalus about half the time. A shunt is required for the other patients. The role of radiation or chemotherapy is still being investigated, but might be recommended for inaccessible or partially resected tumors.

Craniopharyngioma

This is a benign tumor arising from small nests of cells located near the pituitary stalk. Craniopharyngiomas represent 2-3% of all primary brain tumors, and 5-13% of childhood brain tumors. About sixty percent of craniopharyngiomas occur in patients older than sixteen.

Adamantinomatous (ordinary) craniopharyngioma occurs in children and tends to be more cystic than the papillary craniopharyngioma. The papillary craniopharyngioma occurs in adults and is a more solid tumor.

Craniopharyngiomas occur in the sellar region, near the pituitary gland. They often involve the third ventricle, optic nerve, and pituitary gland. These localized tumors grow by expansion and may reach a large size before they are diagnosed. Malignancy and metastasis are unknown.

Increased intracranial pressure due to obstruction of the foramen of Monro, one of the small tunnels through which cerebrospinal fluid exits the ventricles, accounts for many of the symptoms associated with this tumor. Other symptoms result from pressure on the optic tract and pituitary gland. Obesity, delayed development, impaired vision, and a swollen optic nerve are common.

Surgery to remove the tumor is usually the first step in treatment. If hydrocephalus is present, a shunt may be placed during surgery. That shunt will help drain excess cerebrospinal fluid away from the brain. A form of radiation therapy may be suggested if all visible tumor cannot be removed. This may include a focused form of radiation — such as radiosurgery or conformal radiation — or a radiation source may be implanted into the tumor cavity, such as intracavitary use of radioactive phosphorous. In children younger than 3, radiation therapy may be delayed by the use of surgery or hormone therapies. Because this tumor tends to be located close to the pituitary gland which controls hormone balance in the body, an endocrinologist may become involved in the long-term care plan. An endocrinologist is a doctor trained in treating hormone imbalances.

Cysts

Just like a cyst elsewhere in your body, a cyst in the brain is a tumor-like sphere filled with fluid, similar to a balloon filled with water. Cysts may contain fluid, blood, tissue, or tumor cells. There are specific types of cysts; they are named for the type of tissue from which they arose and for their contents. The most common cysts found in the brain are arachnoid, colloid, dermoid, and epidermoid cysts. Each is described below.

ARACHNOID CYST

An arachnoid cyst (sometimes called a leptomeningeal cyst) is an enlarged, fluid-filled area of the subarachnoid space — the space between the arachnoid and pia mater layers of the meninges which form a membrane-like covering around the brain and spinal cord. Arachnoid cysts occur in both adults and children. Their most common locations are in the area of the Sylvian fissure, the cerebellopontine angle, the cisterna magna or the suprasellar region of the brain. The usual treatment is surgery to drain and remove the outermost lining of the cysts. Some surgeons choose to place a shunt to divert the cyst fluid to other areas of the body. Shunting may also be required if the cyst is blocking the flow of cerebrospinal fluid in the brain.

COLLOID CYST

The third ventricle is the most frequent location of the benign colloid cyst. Malignant forms are unknown. This cyst almost always occurs in adults. It is typically attached to the roof of the third ventricle and the choroid plexus. This location may block the flow of fluid through the foramen of Monro, one of the small tunnels through which cerebrospinal fluid exits the ventricles, causing increased intracranial pressure. Headache is the most common symptom.

Various surgical approaches, stereotactic directed cyst drainage or shunting are some of the treatment options for the colloid cyst. Removing this cyst without causing undue damage can be challenging because of its location on/near the third ventricle, and the "best" treatment is dependent on individual patient's anatomy and the configuration of their cyst.

DERMOID CYST

Dermoid cysts likely form during the early weeks of fetal development even though the symptoms may not be noticed for years after birth. As an embryo is developing, the neural tube — the cells which will eventually form the brain and spine — begins to separate from the cells which will become the skin and bones of the face, nose, and vertebrae. A dermoid cyst results when cells that normally belong to the face are diverted to the brain or the spinal cord. That's why the inside of a dermoid cyst often contains hair follicles, bits of cartilage, or sebaceous glands which produce skin oils and fats. On rare occasions, a dermoid cyst may spontaneously open, releasing these oils into the brain or spinal cord.

Dermoid cysts are relatively rare masses to be found in the brain — epidermoid cysts are far more common. However, when a dermoid cyst is found in the brain it is usually a benign mass. These cysts are usually located in the posterior fossa (the lower back portion of the brain) or the adjacent meninges (the thin membranes which form the covering of the brain and spinal cord). Dermoid cysts in the brain tend to occur in children under 10 years old. The lower end of the spine is the more common location in older children and young adults. The cavity of the fourth ventricle and the base of the brain under the surface of the frontal lobes are also common sites.

The standard treatment for a dermoid cyst is surgical removal. If the cyst is unable to be completely removed, it will likely regrow. That growth may be very slow, and it may be years before symptoms would again return.

EPIDERMOID CYST

Also called Epidermoid Tumor

Epidermoid cysts, also referred to as epidermoid tumors, likely form during the early weeks of fetal development even though the symptoms may not be noticed for several decades into life. As an embryo is developing, the neural tube — the cells which will eventually form the brain and spine — begins to separate from the cells which will become the skin and bones of the face, nose, and vertebrae. An epidermoid cyst results when cells that normally belong to the face and bones are diverted to the brain. That's why the inside of an epidermoid tumor often contains remnants of skin cells or tiny pieces of cartilage. On rare occasions, a epidermoid cyst may spontaneously open, releasing these contents into the brain or spinal cord.

Epidermoid cysts occur more frequently in the brain than in the spine, and are a fairly common type of cyst to be found in the brain. They are usually benign, and are most commonly found in middle-aged adults. These cysts tend to be located near the cerebellopontine angle (the area where the top part of the brain meets the brain stem) and near the pituitary gland. Standard treatment is surgical removal. If the cyst is unable to be completely removed, it can re-grow. That growth may be very slow, and it may be years before symptoms would again return.

Dysembryoplastic Neuroepithelial Tumor (DNET)

DNETs are slow growing, benign, grade I tumors. Traditionally seen as similar in appearance and behavior to an oligodendroglioma, recently developed laboratory testing allows pathologists to separate this tumor from other similar appearing tumors. These tumors tend to contain a mix of neurons (nerve cells) and glial (supportive) cells suspended in a mucous-like substance. Although they occur in both adults and children, this tumor tends to be found in people ages twenty to thirty. It is not unusual for the diagnosis to be preceded by a long history of uncontrollable seizures of the partial complex type. DNETs have been occasionally associated with a history of neurofibromatosis type I.

The DNET is most commonly located in a temporal or frontal lobe of the brain. Surgery alone often provides long term control for this tumor, even when the tumor is unable to be completely removed.

Ependymoma

Ependymomas arise from ependymal cells which line the ventricles of the brain and the center of the spinal cord.

EPENDYMOMA

Ependymal cells line the ventricles of the brain and the center of the spinal cord.

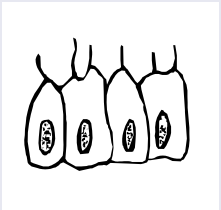

These are relatively rare tumors, accounting for 2-3% of all primary tumors. However, they are the most common brain tumor in children. About one-third of pediatric brain tumors are diagnosed in children under the age of three. Ependymomas are soft, greyish or red tumors which may contain cysts or mineral calcifications. They are divided into four major types: *myxopapillary ependymomas, subependymomas, ependymomas and anaplastic ependymomas*. Many pathologists also assign a number to ependymomas. The grade is based on how much the cells look like normal ependymal cells, although various grading systems exist. The cells of a grade I tumor look somewhat unusual, whereas grade IV tumor cells look definitely abnormal.

Myxopapillary ependymomas tend to occur in the lower part of the spinal column. Subependymomas usually occur near the ventricle. Both of these ependymoma types are uncommon in children. They are slow growing, and are considered to be low-grade or grade I tumors. Ependymomas are the

most common, and are considered grade II tumors. Anaplastic ependymomas are high-grade tumors (grades III or IV) and tend to be faster growing than the low-grade tumors.

The first step in the treatment of an ependymoma is surgery to remove as much tumor as possible. The amount of tumor that can be removed, however, depends on the location of the tumor. Radiation therapy is usually recommended for older children and adults following surgery, even if all visible tumor was removed. If the tumor is localized, radiation therapy is usually given just to that area of the brain. If the tumor has spread, radiation is usually given to the entire brain and spine, with an extra amount of radiation (called a boost) given to the area of the brain where the tumor started. In general, the role of chemotherapy in newly diagnosed ependymomas is not clear, however, it may be used to treat recurrent tumors or to delay radiation therapy in very young children.

We offer additional information specifically about ependymoma and about brain tumors in children. Please call our office if you would like that information.

Gangliocytoma and Ganglioglioma

These rare, benign tumors arise from ganglia-type cells, which are groups of nerve cells. Gangliocytomas (sometimes called ganglioneuromas) are tumors of mature ganglion cells. Gangliogliomas are tumors of both mature nerve and supportive cells.

Tumors arising from ganglia most frequently occur in children and young adults. They represent less than 1% of all primary brain tumors and about 4% of all pediatric brain tumors.

NERVE CELL

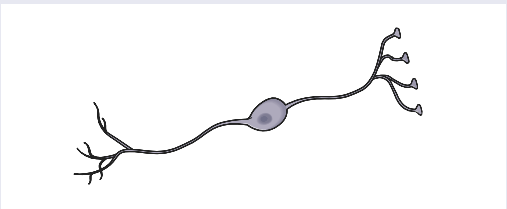

These tumors are most commonly located in the temporal lobe of the cerebral hemispheres and the third ventricle, although they might also occur in the spine. These tumors are small, slow growing, and have distinct margins. Metastasis and malignancy are very rare.

Cyst formation and calcification can be present. Seizures are the most common symptom.

The standard treatment for gangliocytoma and ganglioglioma is surgery.

Germ Cell Tumors

See also the specific type of germ cell tumor

These uncommon tumors represent 1–3% of childhood brain tumors and occur primarily in young people between the ages of 11 and 30. Germ cell tumors arise in the pineal or suprasellar regions of the brain. Included in this type of tumor are the germinoma, the teratoma, the more aggressive embryonal carcinoma and yolk sac (endodermal sinus) tumors, and the choriocarcinoma. Mixed germ cell tumors also exist. Because all these tumors tend to spread via the cerebrospinal fluid (CSF), diagnosis includes evaluation of the entire brain and spinal cord. An MRI scan with gadolinium enhancement and examination of the CSF for the presence of tumor cells is used for that evaluation.

Germ cell tumors are the only primary brain tumors that might be diagnosed by tumor markers found in the cerebrospinal fluid and blood. The markers are alpha-fetoprotein (AFP), placental alkaline phosphatase (PAP) and human chorionic gonadotropin (HCG). More commonly, however, the markers are used to monitor the effectiveness of therapy and to detect recurrence.

Because of its location, a germ cell tumor is often treated with chemotherapy or a combination of radiation and chemotherapy rather than surgery, although a biopsy to establish an exact diagnosis is not uncommon.

Germinoma

The germinoma is the most common type of germ cell tumor in the brain. It typically occurs in the pineal or suprasellar region of the brain. Because it tends to spread via the cerebrospinal fluid, diagnosis includes evaluation of the entire brain and spinal cord. An MRI scan with gadolinium enhancement and examination of the CSF for the presence of tumor cells is used for that evaluation.

The germinoma is the most common tumor of the pineal region representing about 30% of those tumors. Its occurrence is more usual in teen-aged children, and in males more often than females.

Tumors in the pineal region typically cause symptoms indicating increased intracranial pressure. Headache due to obstructed cerebrospinal fluid flow is the most common symptom. If the tumor is in the suprasellar location, symptoms include diabetes insipidus, vision changes, signs of hormonal dysfunction such as fatigue, poor appetite, delayed or absent puberty, and changes in the menstrual cycle.

Surgery for germinoma depends on its accessibility and position relative to critical brain structures. The germinoma is very responsive to radiation and this can be an effective treatment for some patients. Chemotherapy might be the treatment of choice for some newly diagnosed tumors. Chemotherapy can also be useful for recurrent tumors.

Glioblastoma Multiforme (GBM)

Also called "astrocytoma, grade IV"

"Glioblastoma," "glioblastoma multiforme," "grade IV astrocytoma," and "GBM" are all names for the same tumor. Glioblastomas arise from astrocytes, which are star-shaped cells supporting the other cells in the brain. These tumors represent about 20% of all primary brain tumors and about 50% of the gliomas. They are more common in older adults, and affect more men than women. Only nine percent of childhood brain tumors are glioblastomas.

Glioblastomas are generally found in the cerebral hemispheres of the brain, but can be found anywhere in the brain or spinal cord. Because glioblastomas can grow rapidly, the most common symptoms are usually due to increased pressure in the brain and can include headache, nausea, vomiting and drowsiness. Depending on the location of the tumor, patients can develop a variety of other symptoms such as weakness or sensory impairment on one side of the body, seizures, memory or language impairment, and visual changes.

Glioblastomas may arise from a lower grade astrocytoma (grade II or III) or start as a grade IV tumor. Regardless of their origin, all glioblastomas are grade IV tumors because they have several features of rapidly growing tumors — abnormal and numerous blood vessels, as well as dead tissue called necrosis. Since these tumors arise from normal brain they easily intermingle with the normal brain tissue as well as invade and migrate away from the main tumor; however, glioblastoma will rarely spread elsewhere in the body. In addition, several clusters of cells may be resistant to radiation and chemotherapy. All of these factors make these tumors a challenge to treat.

The first step in treating a glioblastoma is surgery to make a diagnosis, relieve pressure, and safely remove as much tumor as possible. Because this tumor has octopus-like tentacles that invade and migrate into the surrounding normal brain, there are no clear edges to glioblastomas. This feature makes them very difficult to remove "completely." If the tumor is located near important structures such as the language center or motor area, the ability to remove most of the tumor may be further limited.

Radiation therapy almost always follows surgery or biopsy. Radiation therapy affects mostly replicating cells and therefore causes more damage to tumor cells than to normal brain cells (most cells in the brain are not actively dividing). The most common type of radiation is called fractionated external beam radiation, meaning that the radiation is given in several treatments over a few weeks. External beam radiation is also called standard radiation or conventional radiation. It is given to the tumor and a margin around it, but not to the whole brain. Other types of radiation sometimes

used for glioblastomas include stereotactic radiosurgery (an intense and focused dose of radiation), brachytherapy (consisting of either implanted radioactive seeds or catheters with temporary radioactive sources in the tumor), liquid radiation in an inflatable balloon instilled after tumor resection, or monoclonal antibodies tagged with radioactive particles.

Chemotherapy may be given before, during or after radiation therapy. Like radiation, chemotherapy affects replicating cells and can have a selective effect on tumor cells. Chemotherapy can also help radiation work more efficiently. Systemic chemotherapy, delivered to the brain through the blood, reaches the tumor cells wherever they are in the brain including those that may not have received radiation. The most commonly used drugs for adults are BCNU, procarbazine, temozolomide (Temodar), or irinotecan. Biodegradable wafers containing BCNU may be placed in the cavity created by tumor removal. New agents, dosages and delivery methods are under investigation. Chemotherapy is often used in children under the age of three to delay radiation.

Another category of drugs that acts differently than chemotherapy and can be used in glioblastoma is "cytostatic" or "biological" agents. These agents interfere with different activities of tumor cells:

- communication with other tumor cells and with the environment or message transmission within the tumor cell (e.g., tamoxifen)
- invasion and migration in the normal brain (e.g., marimastat)
- angiogenesis, the process by which the tumor is building up new vessels to increase its blood supply so it can continue to grow (e.g., thalidomide, endostatin)
- dedifferentiation, the process by which a tumor cell becomes more malignant or different from a normal cell (e.g., 13-cis-retinoic acid).

Immunotherapy uses the body's own immune system to fight a tumor. Several strategies are in study, including:

- use of proteins called cytokines involved in immune system regulation (e.g., interferon, interleukin, TNF)
- use of vaccines with either tumor cells and/or immune cells
- use of proteins called antibodies directed specifically to tumor cells and tagged with either a toxin (e.g., diphtheria, pseudomonas toxins), a drug, or a radioactive compound to destroy tumor cells.

Gene therapy is a very promising and targeted way to treat tumors like glioblastoma. It usually uses a transporter (vector) which is generally a virus. Several strategies are currently under investigation and include:

- genes that prevent tumor cells from replicating and/or cause cell death (apoptosis)
- genes promoting the production of molecules that interfere with mechanisms used by the tumor cells outlined above
- genes that make tumor cells more sensitive to certain drugs
- some viruses specifically-engineered (meaning with gene modification) to replicate only in tumor cells and therefore cause cell death (oncolytic virus).

A major obstacle in gene therapy success is inadequate delivery of the genes and its vector to all tumor cells.

The outcome of glioblastomas not only depends on treatment but also on the patient's age and functional status (how the patient is functioning in daily life and how much impairment is present). Unfortunately, glioblastomas have the potential to recur even with the best treatment. If a recurrence is confirmed the same treatment principles apply. Further surgery, additional forms of radiation (e.g., stereotactic radiosurgery), next-line chemotherapy, biological agents or agents under investigation can all be considered.

We offer additional information about glioblastoma, new treatment options, and family support services. Please contact us to access those services. There are also many clinical trials open to those with either a newly diagnosed or a recurrent glioblastoma; the Cancer Information Service will help you find these trials. CIS can be reached at 800-422-6237.

Glioma

This is a general name for any tumor that arises from the supportive tissue called glia, which help keep the neurons ("thinking cells") in place and functioning well. There are three types of glial cells that can give rise to tumors. An astrocyte (star-shaped cell) will give rise to astrocytomas (including glioblastomas), an oligodendrocyte (cell with short arms forming the insulation of neurons) will give rise to oligodendrogliomas, and lastly, tumors called ependymomas arise from ependymal cells (i.e., the cells that form the lining of the fluid cavities in the brain). Occasionally, tumors will display a mixture of these different cells and are called mixed gliomas.

Names such as "optic nerve glioma" and "brain stem glioma" refer to the location of these tumors, and not the type of tissue that gave rise to them. A specific diagnosis is only possible if a sample of the tumor is obtained during surgery or biopsy.

GLIAL CELLS

Glioma, Brain Stem

Brain stem gliomas usually arise in the "stem of the brain," which contains all the "wires" converging from the brain to the spinal cord as well as important structures involved in eyes movements, face and throat muscle control and sensation. Between 10 and 20% of brain tumors in children are brain stem gliomas. This tumor most often affects children between 5 and 10 years old, but can also be found in adults generally between 30 and 40 years old. Most of these tumors are astrocytomas varying from localized grade I tumors (mostly in children) to infiltrating grade II or III tumors, although many are never biopsy-proven given the high-risk of performing any surgical procedure in that area. However, the diagnosis can usually be based on the MRI scan features.

THE BRAIN STEM: MIDBRAIN, PONS, AND MEDULLA

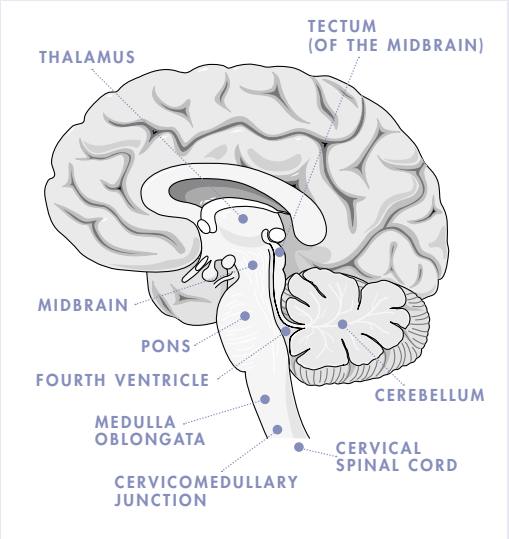

Most of these tumors are classified by their location:

- Upper brain stem (midbrain or tectum)
- Middle brain stem (pons)
- Lower brain stem (cervico-medullary)

and MRI appearance:

- Localized or circumscribed
- Diffusely infiltrating
- Exophytic (meaning the tumor has a knob protruding outside the brainstem)

The majority of brain stem tumors occur in the pons, are diffusely infiltrating, and therefore are not able to be surgically removed. A few of these tumors are localized, and may be reachable for resection. These tumors tend to be very slow growing, not in the pons, and are exophytic — on the outer edges of the brain stem.

The symptoms of a brain stem glioma depend on the location of the tumor. The most common symptoms are related to eye movement abnormalities and cause double vision. Other symptoms include weakness or sensation changes of the face, swallowing difficulty and hoarseness. Weakness, loss/changes in sensation or poor coordination on one side of the body may also occur. The tumor may also block the cerebrospinal fluid circulation resulting in hydrocephalus (dilatation of the fluid cavities in the brain) causing headache, nausea, vomiting and gait unsteadiness.

Treatment of brain stem glioma is dictated by the tumor location, the grade and the symptoms. Surgery may be warranted if a tumor appears circumscribed (contained) or exophytic (on the outside of the brain stem). The goals of surgery are to determine the grade and type of tumor and, sometimes, removal of the tumor. A shunt may also be placed if there is blockage of the cerebrospinal fluid circulation. Radiation therapy may be used early if there are significant symptoms, or it may be postponed until the tumor grows or causes symptoms. A focal type of radiation, such as radiosurgery, can be considered if the tumor appears localized. Chemotherapy is used if the tumor progresses following radiation therapy. Drugs similar to those used to treat glioblastoma may be considered.

Radiation therapy with hyperfractionation (with smaller dose per treatment and many more doses) has been used in children in order to increase the effectiveness of the therapy and decrease side effects. Unfortunately, this has not resulted in significant advantage over standard radiation. Clinical trials using various forms, doses and schedules of radiation therapy for newly diagnosed tumors, and chemotherapy for recurrent tumors are available.

Glioma, Mixed

Mixed gliomas commonly contain a high proportion of more than one type of cell. Most often these tumors contain both astrocytes and oligodendrocytes — these tumors are generally called mixed gliomas or oligoastrocytoma. Occasionally, ependymal cells are also found. The behavior of a mixed glioma tends to be based on the grade of the tumor. It is less clear whether their behavior is closer to that of the most abundant cell type.

Standard treatment for a mixed glioma is similar to that for astrocytoma and oligodendroglioma of the same grade. The treatment plan may includes surgery followed by radiation therapy, particularly if the tumor is high-grade (grade III or IV) although it may also be indicated for lower-grade tumors (grade II). Chemotherapy will generally be used in high-grade tumors. We offer additional information specifically about oligoastrocytoma and oligodendroglioma. Please call our office if you would like that information.

Glioma, Optic

These tumors may involve any part of the optic pathway including the optic nerve right behind the eyeball, the optic chiasm where both optic nerves come together, the optic tracts located close to the brain stem or the optic radiations within the brain. Optic gliomas also have the potential to spread along these pathways. Most of these tumors occur in children under the age of 10. The grade I pilocytic astrocytoma and grade II fibrillary astrocytoma are the most common tumors affecting these structures. Higher-grade tumors may also arise in this location.

Twenty percent of children with neurofibromatosis 1 (NF-1), a genetic disorder affecting the skin and nervous system, will develop an optic glioma. These gliomas are typically grade I, pilocytic astrocytomas. Children with optic gliomas are usually screened for neurofibromatosis (NF) for this reason. Adults with NF-1 generally do not develop optic gliomas.

These tumors may be quiet, causing few or no symptoms. Their placement along the nerves of seeing, however, can cause loss of vision (in one eye or partial vision loss in both eyes depending on the location of the tumor) or strabismus ("crossed eyes"). Hormonal disturbance might also occur causing developmental delay, early puberty and other symptoms.

VISUAL CHANGES WITH TUMORS ALONG THE OPTIC PATHWAY

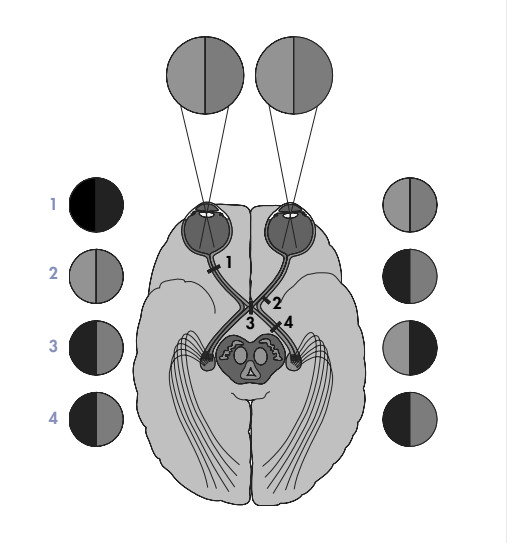

Careful observation may be an option for patients with stable or slow growing tumors. Treatment other than monitoring is based on symptoms or changes seen on the MRI scan. Surgery might be recommended for a growing tumor which involves only the optic nerve. Radiation therapy might be used for a tumor of the chiasm or other pathways. Local radiation therapy and chemotherapy with radiation therapy are used for recurrent tumors. Clinical trials are available for both primary and recurrent tumors.

Gliomatosis Cerebri

This condition is an uncommon primary brain tumor characterized by a diffuse, or broad, spread of glial tumor cells in the brain. This tumor is distinct from other gliomas by its scattered and widespread nature, typically involving two or more lobes of the brain. This tumor could be considered a "widespread low-grade glioma." It also lacks the malignant features (such as abnormal blood vessels' growth and dead tissue) seen with high-grade tumors. The diffuse nature of gliomatosis causes enlargement of any part of the brain it involves including the cerebral hemispheres, or less often, the cerebellum or the brain stem. Symptoms are often nonspecific and can include personality and behavioral changes, memory disturbance, increased intracranial pressure with headache and sometimes seizures. Treatment is less well-defined given the rarity of this tumor. Surgical resection is generally not attempted due to the diffuse nature of that tumor; the diagnosis might be based on biopsy only. Radiation therapy and chemotherapy may be considered.

Glomus Jugulare

See also Paraganglioma

Glomus jugulare tumors are also called paragangliomas. They originate from chemical sensors called chemoreceptors located in the lining of a large vein in the neck called the jugular vein. These tumors are rare, slow growing, usually benign, but can spread to the bone close to the inner and middle ear. This tumor is most often found in people about 50 years old. Most people have symptoms related to the inner ear including hearing loss, abnormal noise in the ear, dizziness, ear pain or bleeding in the external ear canal. Other nerves located close to the jugular vein can be affected and result in facial weakness, hoarseness or swallowing difficulties.

The initial diagnosis of this type of tumor may be made with CT or MRI scanning. These studies show a tumor either at the jugular vein opening at the base of the skull or higher up close to the inner ear canal, cerebellum and brainstem. Cerebral angiography using a dye injected in brain vessels can be helpful in making a diagnosis because this tumor often has a large blood supply. If the tumor "runs in the family," it is not unusual to find multiple tumors in the same person.

Because of the rarity of this tumor the most effective treatment is not well-defined. Surgery appears to benefit young patients with a large tumor causing symptoms. The surgical team often consists of a neurosurgeon and a "head and neck" surgeon. ("Head and neck" is not the same as the "brain." These are separate areas of medicine.) Standard radiation or radiosurgery also appears effective in stabilizing these tumors. Radiosurgery can be used in patients with small tumors or when residual tumor is left after surgery.

Hemangioblastoma

Hemangioblastoma is a benign and slow-growing tumor arising from cells in the blood vessel lining. These cystic tumors tend to have clearly indicted borders and do not infiltrate the surrounding normal tissue. Single or multiple tumors may be present. They are most common in the lowest part of the brain — the posterior fossa, which contains the cerebellum and the brainstem — but can occur in the cerebral hemispheres, the spinal cord or even the retina.

Hemangioblastomas represents about 2% of all primary brain tumors. About 10% of patients with hemangioblastoma have Von Hippel-Lindau disease, an inherited condition that predisposes to this tumor and tumors of the liver, pancreas and kidneys. The tumor can occur at any age but most commonly found in people about 40 years old.

This tumor commonly causes blockage of the cerebrospinal fluid circulation resulting in hydrocephalus (enlarged fluid cavities of the brain) and increased intracranial pressure. It may also compress the cerebellum involved in balance and limbs coordination. The most common symptoms include headache, nausea and vomiting, gait disturbances, and poor coordination of the limbs.

CT or MRI scans can be used to visualize the hemangioblastoma. Angiography is done before surgery to confirm the diagnosis and provide information about the tumor's blood supply.

Surgery is the standard treatment. Incompletely removed tumors or tumors attached to the brain stem might be treated with focused radiation such as stereotactic radiosurgery. Drugs affecting the growth of the blood vessels which feed the tumor (a process called angiogenesis) are being studied for this disease.

For more information about Von Hippel-Lindau disease, contact:

VHL Family Alliance
171 Clinton Road
Brookline, Massachusetts 02445

Phone: 800-767-4845
E-mail: info@vhl.org
Website: www.vhl.org

Hemangiopericytoma

This is a rare grade II or III tumor, different in origin from meningiomas although arising in the same location — the lining of the brain called meninges. These tumors appear to originate in the cells surrounding the blood vessels in the meninges, and this explains the large blood supply within these tumors. They do not invade the brain but have a greater potential than meningioma to recur locally or even spread elsewhere in the body (bone, lung and liver) although the latter does not occur until late in the disease. Hemagiopericytomas affect younger people than meningiomas, and people usually have symptoms for less than a year before diagnosis.

Standard treatment begins with a study of the vessels feeding the tumor (cerebral angiogram) in an attempt to minimize blood loss during surgery. The goal of surgery is to remove as much tumor as possible, yet this is possible in only about 50% of cases. Since these tumors have a tendency to come back, radiation therapy is generally recommended following surgery. Despite best treatment the tumor may recur, and surgery or radiosurgery can be used at that time. Chemotherapy is used if surgery and radiation are not effective, or if the tumor has spread elsewhere in the body. Long-term follow-up with chest x-ray, bone scan, and liver function studies is necessary.

Lipoma

Lipomas are rare, benign tumors composed of fatty tissue. The most common location is in the region of the corpus callosum, but they also occur in other areas in the brain usually close to the midline (the middle part of the brain where the two hemispheres of the cerebral lobes meet). A lipoma may cause no symptoms and is often diagnosed coincidentally when scans are performed for other medical reasons. Some lipomas are associated with other congenital abnormalities of the nervous system. It is diagnosed by either CT or MRI scanning. Conservative treatment is usually recommended since these tumors rarely cause symptoms. Surgery may be suggested in some circumstances.

Lymphoma

Also called CNS Lymphoma, Primary Malignant Lymphoma or Primary CNS Lymphoma (PCNSL)

This disease affects people with healthy immune systems and those whose immune system is not functioning properly — such as organ transplant recipients or people who are HIV positive. CNS lymphoma most commonly originates from B lymphocytes and is classified as non-Hodgkin's (meaning it is different than Hodgkin's disease). The incidence of CNS lymphoma has been increasing over the past 20 years; it now represents between 0.5% and 2% of all primary brain tumors.

Lymphoma occurs most often in the cerebral hemisphere but may also involve the cerebrospinal fluid, the eyes or the spinal cord. In addition, a few people may have evidence of lymphoma elsewhere in the body. It is not unusual for this tumor to be found in multiple places in the cerebral hemisphere as it does have the potential to spread throughout the central nervous system. CT or MRI scans are used to diagnose the presence of this tumor, but a biopsy is required for confirmation since other types of tumor, infections or inflammatory disorders may look the same on the scan. A spinal tap to screen for tumor cells in the cerebrospinal fluid might be performed as long as there is no indication of increased intracranial pressure. Examination of other parts of the body, including the eyes, is often recommended to determine if the tumor has spread.

The most common symptoms of CNS lymphoma include personality and behavioral changes, confusion, symptoms associated with increased intracranial pressure (headache, nausea, vomiting, drowsiness), weakness on one side of the body and seizures. Problems with eyesight, such as blurred vision, floaters or double vision may also occur.

Since the tumor may be widespread in the brain, a biopsy is often enough for diagnosis. A resection (surgical removal of the tumor) may only be performed if there is significant pressure. After the diagnosis of lymphoma is confirmed, steroids are used to control brain swelling; this may result in the immediate disappearance of the tumor on a subsequent scan. Lymphoma responds very well to treatments such as radiation or chemotherapy. Radiation therapy has been the standard therapy for many years. Chemotherapy can be used before or after radiation, or in place of radiation to provide greater control. If the peron has no or minimal neurological symptoms, s/he may be treated with an intravenous chemotherapydrug called methotrexate, and radiation may be deferred. Tumor regrowth, if it occurs, may be treated with the same chemotherapy or another drug may be used. Radiation to the entire brain is used for patients with significant impairment of their functions or at the time of tumor recurrence.

Medulloblastoma (MDL)

Medulloblastoma represents 15-20% of pediatric brain tumors. In addition, about 20% of these tumors occur in adults. Medulloblastoma is always located in the cerebellum.

Medulloblastoma is a fast-growing, high-grade tumor which frequently spreads to other parts of the central nervous system. Given its location — close to one of the fluid cavities of the brain called the fourth ventricle — the tumor may also extend into that cavity, block the cerebrospinal fluid circulation, or send tumor cells through the spinal fluid to the spine. It is uncommon for medulloblastomas to spread outside the brain and spinal cord.

The most common symptoms of medulloblastoma, particularly in young children, include behavioral changes, symptoms of increased intracranial pressure such as headache, nausea, vomiting and drowsiness, gait unbalance and poor coordination of the limbs. Unusual eye movements may also occur.

Treatment consists of surgical removal of as much tumor as possible. Testing will also be done to check for possible tumor spread — this would include an MRI of the spine and a cerebrospinal fluid analysis. For older children, adults without evidence of spread and those for whom most of the tumor has been removed, radiation to the tumor area followed by a lower dose of radiation to the entire brain and spinal cord follows surgery. Very young

LOCATION FOR THE CEREBELLUM

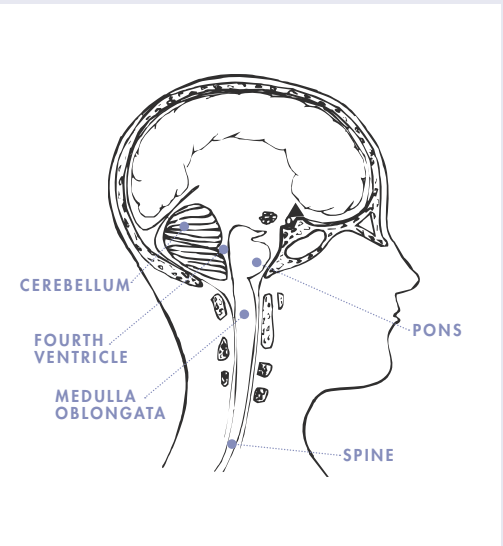

children are often treated with chemotherapy instead of radiation to defer its use until they are older.

"High-risk patients," including children younger than three, those with tumor remaining following surgery, or those with evidence of spread to the spinal fluid or the brainstem may benefit from the addition of chemotherapy. The most commonly used agents include a combination of CCNU and vincristine with either cisplatin or a steroid. Recurrent tumors might require a second surgery and chemotherapy.

Meningioma

These tumors arise from the "arachnoid mater" — one of the layers of the meninges (the lining of the brain). Meningiomas represent about 27% of all primary brain tumors and occur most frequently in middle-aged women. The majority of meningiomas are benign, grade I, slow-growing tumors which are localized and non-infiltrating. Meningiomas are most often located between ("parasaggital meningiomas") or over ("convexity meningiomas") the cerebral hemispheres, at the base of the skull, and in the back, lower part of the brain called the posterior fossa. They occur less frequently in the spine. Most often a single tumor is found, but multiple meningiomas also occur. Risk factors for meningioma include prior radiation exposure to the head, and a genetic disorder called "neurofibromatosis type 2" (see section on NF) which affects the nervous system and the skin; however, meningiomas occur in people who have no risk factors.

MENINGES

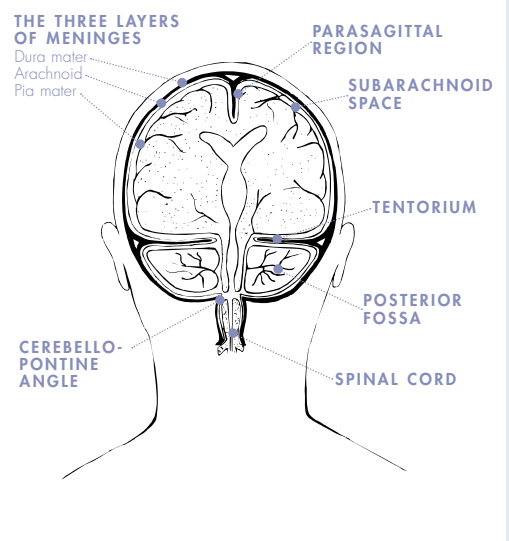

A variety of symptoms are possible, depending on the tumor's location. The most common indications are headache, weakness on one side, seizures, personality and behavioral changes, and confusion.

The benign meningioma (grade I) is slow growing with distinct borders. Because it grows slowly, it can grow quite large before symptoms become noticeable. Symptoms are caused by compression rather than by the tumor growing into brain tissue. If the tumor is accessible, the standard treatment is surgery to remove the tumor, the portion of the dura mater (the outermost layer of the

COMMON LOCATIONS OF MENINGIOMAS

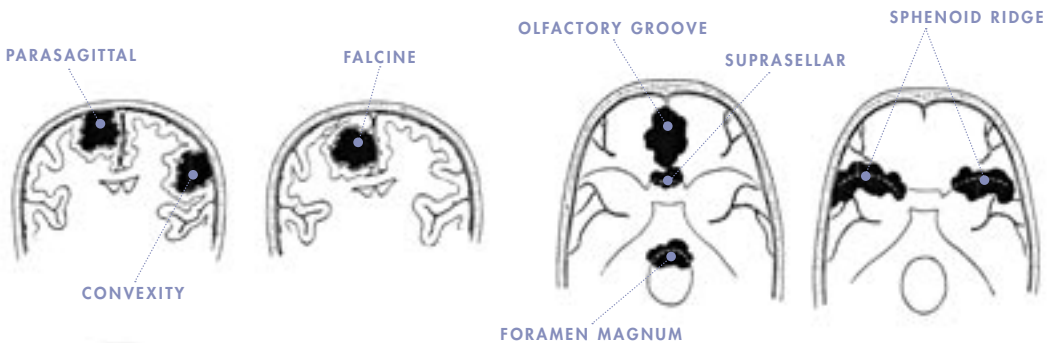

Burger, Scheithauer, and Vogel. *Surgical Pathology of the Nervous System and Its Coverings*. Fourth Edition. Churchill Livingstone, New York, 2002. Diagram reproduced with permission.

meninges) to which it is attached and any bone that is involved. Total removal appears critical for long-term tumor control. Radiation therapy or radiosurgery might be of value if the tumor is not entirely resected. For some patients, surgery may not be recommended. For those with no symptoms (when they have been diagnosed coincidentally), those with minor symptoms of long duration and those for whom surgery would be risky, long-term close observation with scans may be advised. An alternative includes focused radiation, or stereotactic radiosurgery.

The atypical meningioma (grade II) has a middle range of behavior. These tumors are not clearly malignant but they may invade the brain, have a tendency to recur and are faster growing. The diagnosis and grade are determined by specific features that can be seen under the microscope. Radiation therapy is indicated after surgery, particularly if any residual tumor is present.

Anaplastic or malignant meningiomas (grade III) and papillary meningiomas are malignant and tend to invade adjacent brain tissue.They represent less than 5% of meningiomas. Radiation therapy is clearly indicated following surgery regardless of whether residual tumor is present.

Meningiomas may recur, either as a slow-growing tumor or sometimes as a more rapidly growing, higher-grade tumor. Recurrent tumors are treated similarly, with surgery followed by either standard radiation therapy or radiosurgery regardless of the grade of the meningioma. Chemotherapy and biological agents are being studied for recurrent meningioma. Hormone therapy does not appear effective.

We offer additional information about Meningioma. Please call our office if you would like that material.

Metastatic Brain Tumor

A metastatic, or secondary, brain tumor is formed by cancer cells from a primary cancer elsewhere in the body which spread to the brain. In most situations, the primary cancer is diagnosed before it spreads to the brain, but in some circumstances the brain tumors are found the same time or before the primary cancer is found. Cancers that frequently spread to the brain include:

- Lung cancer
- Breast cancer
- A malignant skin cancer called melanoma
- Kidney cancer
- Colon cancer

We offer additional information specifically about metastatic brain tumors. Please call our office if you would like that material.

Neuroblastoma, Cerebral

Neuroblastoma most commonly occurs outside the central nervous system, in the abdomen and chest. It is part of the family of tumor called "PNET." When found in the brain, these are usually malignant, rapidly growing tumors occurring in the cerebral hemisphere. They commonly cause increased pressure within the brain, seizures or weakness on one side. Like the PNET, it has the potential to spread throughout the central nervous system via the cerebrospinal fluid. The assessment and treatment are identical to other PNET and outlined in that section.

Neurocytoma, Central

This rare, grade II tumor typically occurs in the fluid cavities of the brain called the lateral ventricles in the region of the foramen of Monro (the area where the left and the right lateral ventricles come together), and occasionally extends into the third ventricle as well. The central neurocytoma contains mature cells similar to normal neurons — the "thinking cells" of the brain — although their exact cell of origin is unknown. Central neurocytoma is most common in young adult males. These tumors usually block the cerebrospinal fluid circulation causing hydrocephalus (dilatation of the brain fluid cavities). Resulting symptoms are those associated with increased intracranial pressure, such as headache, nausea, vomiting, drowsiness. Seizures may also occur.

Standard treatment is surgery, which is often successful; however, excessive bleeding can limit the extent of tumor removal. The role of

radiation therapy is unclear; however, if the tumor has more aggressive features or if the tumor recurs, radiation therapy may be recommended.

Neurofibromatosis (NF)

The term neurofibromatosis refers to two different genetic diseases characterized by skin abnormalities and nervous system tumors. Neurofibromatosis type I, also called NF-1 or Von Recklinghausen's disease, is the more common of the two disorders. It causes tumors of the nerves, called neurofibromas, throughout the body and often visible underneath the skin. It also causes skin discolorations called "café-au-lait" spots as well as freckles in the arm pits and groin regions. Other nervous system tumors can be associated with NF-1; these occur in approximately 10% of patients and include optic pathway gliomas (usually pilocytic astrocytoma), cerebral hemisphere, posterior fossa (brain stem and cerebellum), and low-grade astrocytomas in the spinal cord.

NF-2-associated nervous system tumors may include tumors of the hearing nerve (acoustic neuromas or vestibular schwannoma) typically on both sides, meningiomas, schwannomas of the spinal root of the nerves, and ependymomas (spinal cord or brain).

The predisposition to tumor formation in both disorders is related to genetic abnormalities which interfere with a protein that normally regulates and prevents tumor formation.

Extensive information about neurofibromatosis is available from:

The National Neurofibromatosis Foundation, Inc.
95 Pine Street, 16th Floor
New York, New York 10005

Phone: 800-323-7938
E-mail: nnff@nf.org
Website: www.nf.org

or

Neurofibromatosis, Inc.
9320 Annapolis Road, Suite 300
Lanham, Maryland 20706

Phone: 800-942-6825
E-mail: info@nfinc.org
Website: www.nfinc.org

Oligodendroglioma

These tumors arise from oligodendrocytes, one of the types of cells that make up the supportive, or glial, tissue of the brain. Under the microscope these tumor cells seem to have "short arms" or a fried-egg shape as opposed to astrocytomas, which have "long arms" or a star-like shape. Oligodendrogliomas can be low-grade (grade II) or high-grade (grade III also called anaplastic). Sometimes oligodendrogliomas may be mixed with other cell types. These tumors may also be graded using an "A to D" system which is based on microscopic features such as the appearance of the cell nucleus, the number of blood vessels, and presence or absence of dead tissue called necrosis. The grade denotes the speed with which the tumor cells reproduce and the aggressiveness of the tumor.

OLIGODENDROCYTE

Oligodendrocytes are one of the types of cells that make up the supportive, or glial, tissue of the brain.

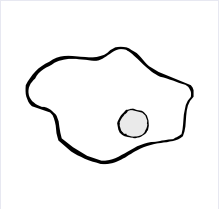

Oligodendrogliomas occur most frequently in young and middle-aged adults, but can also be found in children. The most common location is the cerebral hemisphere, with about half of those tumors being found in the frontal lobe. Seizure is the most common initial symptom, particularly in low-grade tumors.

Standard treatment for accessible tumors is surgical removal of as much tumor as possible. Biopsy alone may be performed for inaccessible tumors — those that cannot be surgically removed. The tumor sample removed during a biopsy is used to confirm the diagnosis and the grade of tumor.

For low-grade oligodendroglioma that appear on the MRI scan after surgery to have been completely resected, close observation with MRI may be recommended. If some of the tumor remains after surgery (this is called "residual" tumor), radiation therapy appears to be indicated although the best timing

— immediately or at tumor progression — is being determined in clinical trials. For anaplastic oligodendroglioma, a combination of radiation therapy and chemotherapy such as PCV (procarbazine, CCNU and vincristine) or temozolomide is indicated. Recurrent low-grade oligodendrogliomas can be treated with surgery, radiation therapy (if not given initially), or chemotherapy. Recurrent anaplastic oligodendroglioma may be treated with surgery and/or chemotherapy. Clinical trials are available for newly diagnosed and recurrent, low-grade or high-grade oligodendrogliomas.

We offer additional information about oligodendroglioma. Please call our office if you would like that material.

Pineal Region Tumors

The pineal gland is located at the rear of the third ventricle — one of the fluid cavities of the brain. Pineal region tumors represent less than 1% of all primary brain tumors; however, 3% to 8% of childhood brain tumors occur in this area. Several tumor types may occur in this area:

- Germ cell tumors including germinoma (tumor similar to other occurring in testes or ovaries), and non-germinoma (including several such as teratoma, endodermal sinus tumor, embryonal cell tumor, choriocarcinoma and mixed tumors)
- Pineal cell tumors including pineocytoma, pineoblastoma, and mixed tumor
- Other tumors including meningioma, astrocytoma, ganglioglioma, and dermoid cysts. *Please see these individual tumor types for additional information.*

PINEAL TUMORS
PINEOCYTOMA
PINEOBLASTOMA
MIXED PINEAL TUMOR

These tumors originate from normal cells of the pineal gland — a gland located in the center of the brain involved in the secretion of specific hormones. The pineocytoma is a slow-growing, grade II tumor. Pineoblastoma is the more aggressive, grade IV, malignant counterpart. A grade III intermediate form has also been described. These tumors tend to occur in young adults between the age of 20 and 40 years. About 10-20 % of the tumors, particularly the pineoblastoma, have the potential to spread through the cerebrospinal fluid. This usually occurs late in the disease. The tumors, however, rarely spread elsewhere in the body.

Symptoms are most often due to obstruction of cerebrospinal fluid flow and involvement of the eye movement pathways. Headache, nausea and vomiting, and double vision are common.

CT and MRI scans are used to visualize the tumor and determine if it has spread. If a biopsy or surgery is not considered, cerebrospinal fluid analysis may be used to rule out other tumor types occurring in the same area.

Surgery may be possible in some individuals to determine the tumor type and to remove part of the tumor. If surgical removal is not possible, biopsy may be considered — depending on the risks involved — for purposes of obtaining a tissue sample for pathological examination and confirmation of the diagnosis. Some patients require placement of a shunt to relieve the cerebrospinal fluid obstruction.

The standard treatment for these tumors is radiation therapy. Conventional radiation therapy to the pineal region is standard, although a form of focused radiation may be considered. Radiation of the entire brain and spinal cord is generally recommended for pineoblastoma. Chemotherapy may also be considered, particularly if the tumor has spread or if the tumor regrows.

Pituitary Tumors

The pituitary gland is involved in the secretion of several essential hormones. Tumors arising from the pituitary gland itself are called adenomas. Adenomas are benign and slow growing tumors. These tumors represent approximately 10% of primary brain tumors. Pituitary adenomas occur at any age but incidence increases with age. Women are more affected than men, particularly during childbearing years.

Most pituitary adenomas grow in the front two-thirds of the pituitary gland, which is called the adenohypophysis. The tumors are classified as "secreting" or "non-secreting." A "secreting tumor" produces excessive

PITUITARY GLAND

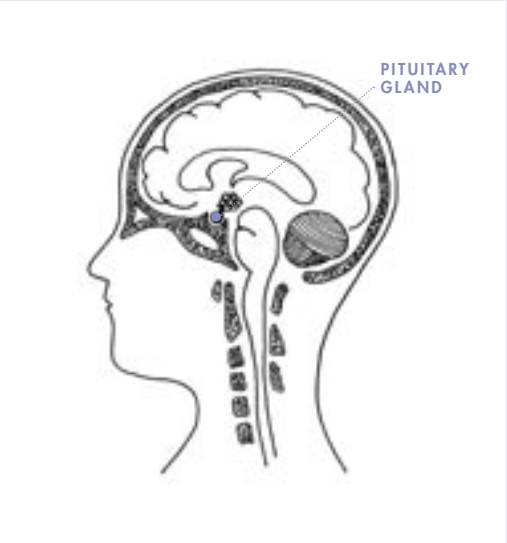

amounts of hormones. The majority of pituitary adenomas are secreting tumors, and are further classified by the hormone(s) being secreted.

Symptoms are caused by the growing tumor pushing on surrounding structures, by excessive hormone production, or by impaired hormone production. The hormones most commonly affected include growth hormone (which regulates body height and structure), prolactin (which controls lactation, or milk production), the sex hormones (which control the menstrual cycle and other sexual functions), thyroid gland hormones, adrenal gland hormones and vasopressin (which is involved in water and electrolyte balance). Pressure on surrounding structures most commonly causes headache, visual impairment, and behavioral changes.

MRI scan is used to determine the tumor size and position in relation to other brain structures. Several blood tests can be performed to determine which hormones are elevated or reduced.

Because hormones affect other parts of the body, treating a pituitary tumor is a team effort involving many specialists including a neurosurgeon, an endocrinologist and an ophthalmologist. Usually therapy includes surgery for tumor removal using an approach through the nose and sinuses. However, for a small prolactin-secreting pituitary adenoma, the drug, bromocriptine, may be used to reduce tumor size without surgery. Other tumor-shrinking drugs may be used after surgery depending on the type of hormone the tumor is secreting. Radiation therapy is used for a persistent or recurrent tumor that is not responding to drugs (if the tumor is secreting). For non-secreting tumors, radiation may be used following a partial removal or if the tumor was invasive. Replacement hormone therapy is often prescribed following surgery and/or radiation.

The pituitary carcinoma is the rare malignant form of the pituitary adenoma. It is diagnosed only when there is proven spread (metastases) inside or outside the nervous system. Symptoms are identical to those of the adenoma; this tumor may also secrete a variety of hormones. Treatment may include surgery, radiation therapy, hormone therapy, and chemotherapy.

PNET — Primitive Neuroectodermal Tumor

PNET is a name used for tumors which appear identical under the microscope to the medulloblastoma, but occur primarily in the cerebrum. PNET is used by some to designate tumors such as the pineoblastoma, polar spongioblastoma, medulloblastoma and medulloepithelioma. With the exception of the medulloblastoma, all of these are very rare tumors.

PNETs most frequently occur in very young children. The tumors contain undeveloped brain cells, are highly malignant, and tend to spread throughout the central nervous system.

PNETs commonly contain areas of dead tumor cells (necrosis) and cysts. Laboratory tests help differentiate this tumor from other types. CT scans can show cysts and areas of calcification which are common in PNETs. Surrounding edema is uncommon. MRI scans can provide an indication of tumor size.

Because they tend to be large tumors, symptoms of increased intracranial pressure and mass effect are usual. Seizures are common.

Surgery is the standard initial treatment for these tumors. Because of their large size and tendency to spread, as well as their extensive

blood supply, total surgical removal is rarely achieved. In children older than three and in young adults, radiation therapy routinely follows surgery, with delivery to the entire brain and spine. Doses are similar to those used for medulloblastoma. Younger children are often treated with chemotherapy instead of radiation therapy, until they are older.

The chemotherapy used for medulloblastoma might also be effective against a PNET. Many clinical trials using chemotherapy and combinations of therapy are available for the medulloblastoma and PNET.

Pseudotumor Cerebri

Also called Primary or Idiopathic Intracranial Hypertension.

The cause of this condition is unknown, but it is not due to a brain tumor. Pseudotumor cerebri literally means "false brain tumor" since there is increased pressure of the spinal fluid, which causes symptoms of increased intracranial pressure as with a tumor. It is most common in young or middle-age individuals.

Headaches, vision changes, and other symptoms of increased intracranial pressure are usually present. Diagnosis is generally confirmed by a spinal tap which measures spinal fluid pressure. Scans are used to be sure an actual tumor does not exist.

Treatment consists of relieving the symptoms and saving vision. Pressure may be controlled by medications which reduce the production of cerebrospinal fluid. Vision will be closely monitored during treatment. If vision is threatened, surgery may be considered to decrease pressure on the optic nerves. Or, a shunt may be placed to move spinal fluid to another area of the body.

For more information on pseudotumor cerebri, contact:

Intracranial Hypertension Research Foundation
6517 Buena Vista Drive
Vancouver, WA 98661

Phone: 360-693-4473
Email: info@IHRFoundation.org
Website: www.ihrfoundation.org

Recurrent Tumors

Many tumors cannot be removed completely during surgery because they have invaded the surrounding normal tissues. Some tumors such as low-grade gliomas (astrocytomas and oligodendrogliomas) and meningiomas have the potential to recur as higher-grade or more aggressive tumors. If they recur, a second surgery may be indicated. Conventional radiation therapy can be given if it was not used initially. A form of focused radiation therapy, such as radioactive implants or stereotactic radiosurgery might be recommended if conventional radiation therapy has already been given. Chemotherapy is frequently used to treat recurrent tumors. Clinical trials with chemotherapy and biologic therapies are available, particularly for recurrent high-grade gliomas.

Schwannoma

See Acoustic Neuroma

Skull Base Tumors

Tumors located along the bones that form the bottom of the skull or along the bony ridge in back of the eyes are called skull base tumors. These tumors are most often chordomas, meningiomas, glomus jugulare, schwannomas or metastatic tumors.

SKULL BASE

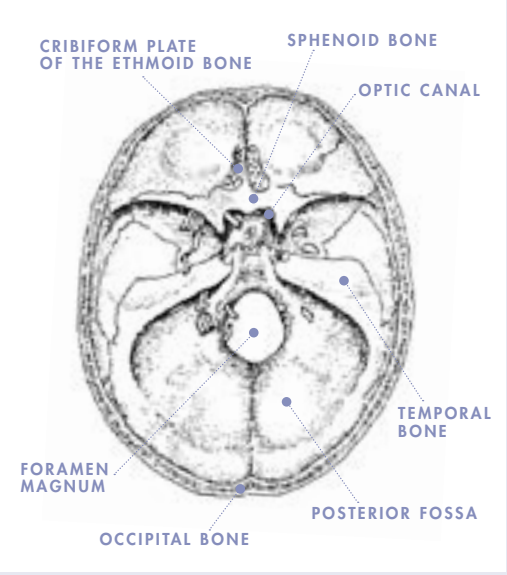

Skull base tumors are diagnosed by MRI or CT scans. Treatment depends on the type and location of the tumor, and well as its surgical accessibility. Newer surgical tools and stereotactic techniques help the neurosurgeon remove large portions of these tumors. A team approach might be used with extensive tumors: a neurosurgeon, an ear, nose and throat (otorhinolaryngology) specialist, a surgeon with training in cranio-facial surgery, and/or a plastic surgeon.

Outcome depends on the extent of tumor removal and the type of tumor. Recurrent tumors might be treated with a second surgery or focused radiation such as stereotactic radiosurgery. Radiation might also be used for partially removed or metastatic tumors.

Spinal Cord Tumors

The types of tumors found in the spine vary by location. Tumors commonly found on the outermost layer of the spinal cord lining, called the dura mater or the epidural area, include metastases from cancers which began elsewhere in the body as well as cancers which tend to be found near the spinal cord, such as sarcoma, neuroblastoma, and multiple myeloma. Tumors found within the dura mater but located outside the actual spinal cord substance (intradural/extramedullary) include meningioma, schwannoma, neurofibroma, and other rare tumors. Finally, tumors arising within the spinal cord substance (intramedullary) include astrocytoma, ependymomas, and less commonly, metastases.

CROSS SECTION OF VERTEBRA AND SPINAL CORD

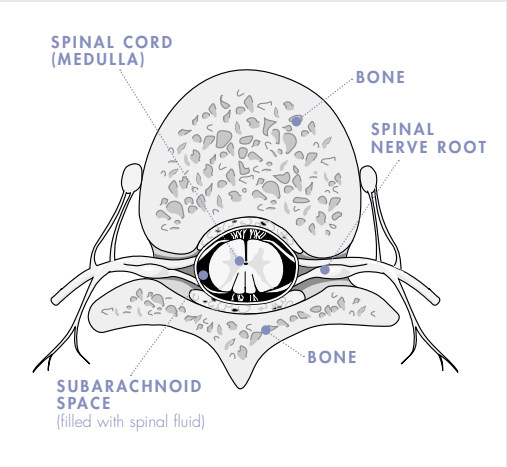

Some symptoms of spinal tumors are due to compression of the spinal cord and usually have a gradual onset. Pain and leg weakness are the most common. If the tumor infiltrates the spinal cord, pain is less common and weakness, sensory impairment, and bladder control difficulty are more often seen.

Treatment of spinal tumors depends on whether the tumor is primary or metastatic, its location and the type of tumor. Epidural tumors are usually treated with radiation with or without surgery. Surgery is the standard treatment for intradural, extra-medullary tumors arising in the spinal canal. Intramedullary tumors may be treated with surgery and radiation may be indicated if residual tumor is left or if the tumor is high-grade.

SPINE

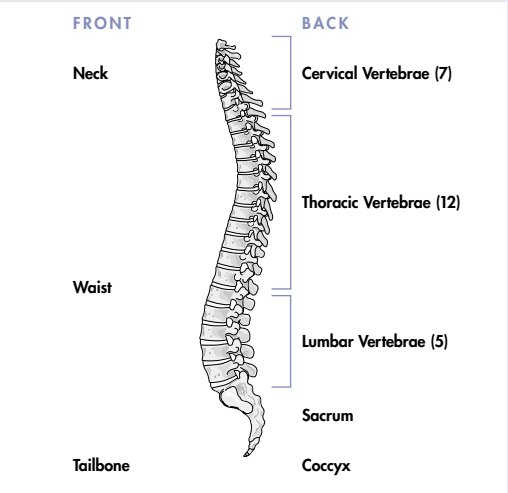

Teratoma

A teratoma is characterized by the presence of the tissue types within the tumor — the tissue can be "mature" (developed cells) or immature (undeveloped). The mature teratoma is a rare, benign germ cell tumor which most frequently occurs in male infants and children. Teratomas represent 18-20% of all germ cell tumors. They often contain calcium, cysts, fat and other soft tissues. Teratomas are most frequently found in the rear of the third ventricle near the pineal gland and above the pituitary gland. This germ cell tumor is the least likely to spread via the cerebrospinal fluid.

Teratomas are the most common brain tumor in newborns. The majority of teratomas occur in children and adolescents. The symptoms vary with the location (see sections on pineal region tumors and pituitary tumors). MRI scan and evaluation of the cerebrospinal fluid for tumor cells help determine if the tumor has spread.

Because obstruction of cerebrospinal fluid circulation occurs in most patients with pineal region tumors, a shunt is often needed to reduce the size of the ventricles before any other treatment can be performed. Surgery is the standard treatment for accessible tumors and can be curative. If surgery is not practical, a biopsy to establish an exact diagnosis may be possible. Radiation therapy may follow surgery or be used for inoperable or partially removed tumors particularly if immature. For children under the age of three, chemotherapy to delay radiation might be recommended.

Toxoplasmosis

This is an infection of the central nervous system caused by a small parasite, Toxoplasma gondii. The parasite is found in the intestines of cats and in uncooked meats. Most people can be exposed to this parasite and never develop symptoms. At risk for severe disease are individuals with compromised immune systems such as AIDS patients, those who have undergone organ transplants, and those who, for other reasons, have an abnormal immune system.

The disease is suspected when seen on MRI or CT scans, but may also appear similar to metastases or primary CNS lymphoma. The disease is usually diagnosed by a 2-3 week trial of drug treatment followed by a scan to assess response. If growth or no response is seen, a biopsy is performed.

Treatment consists of drugs aimed at controlling the infection, including anti-parasitic agents. Drug treatment may continue indefinitely in people with AIDS because of the likelihood of recurrence. Blood tests are used to monitor drug levels. Steroids can be given to control swelling of brain tissue.

Tuberous Sclerosis (Bourneville's Disease)

Tuberous sclerosis is a hereditary disorder affecting the nervous system and the skin as well as other organs. It is an autosomal dominant genetic disorder meaning the child has a fifty-fifty chance of inheriting tuberous sclerosis if a parent has this disorder. In addition, this disease may result from a sporadic mutation (the first case in a family) in 50–60% of patients. Tuberous sclerosis becomes obvious in childhood when seizures occur and skin nodules appear on the face.

Subependymal giant cell astrocytoma is the brain tumor associated with tuberous sclerosis. It often occurs near the foramen of Monro (the narrow channel, also called the interventricular foramen, between the lateral ventricles and the third ventricle through which cerebrospinal fluid flows). This tumor occurs in 5–7% of patients with tuberous sclerosis. Management of this tumor includes a shunt to relieve the cerebrospinal fluid obstruction but surgery is the cornerstone of treatment. Radiation and chemotherapy have no role.

Continuing follow-up for tuberous sclerosis and genetic screening for family members is available through tuberous sclerosis clinics.

For more information on tuberous sclerosis, contact:

National Tuberous Sclerosis Alliance
801 Roeder Road, Suite 750
Silver Spring, Maryland 20910

Phone: 800-255-6872
Email: info@tsalliance.org
Website: www.tsalliance.org