Chapter 5

Diagnosis & Follow-Up

Initially, the question is whether or not you have a brain tumor. If you do, the next step is to determine the type of tumor. In this chapter we outline the various tests your health-care team may order to make that diagnosis.

Some of the same tests used to first diagnose your tumor are also used to monitor your progress — to see if the tumor disappeared, is shrinking, remains the same or has changed. Follow-up care for a brain tumor might extend for years or even a lifetime, not unlike many other medical conditions.

Understanding the tests — what they are, how they work, and what they can or cannot show — can help you feel more comfortable and in control. If at any time you have questions about the tests ordered for you, feel free to ask. Your nurses, and the professionals giving these tests, can provide answers, fact sheets, instructional materials, and the reassurance you need to make you feel at ease with these procedures.

Making a Diagnosis

Your doctor begins to make a diagnosis by taking your medical history. You are asked to describe your symptoms, how long you have had them, when they occur, if they seem to be brought on by something in particular, the order of their appearance, and if they seem to be getting worse. Following the question and answer phase of the process, your doctor will perform a basic neurological examination in the office.

Neurological Exam

A basic neurological examination includes the following:

- tests for eye movement by following a moving finger; pupil reaction, and eye reflex using a pen light
- vision tests and examination of the optic nerve
- hearing tests using a ticking watch or tuning fork
- reflex tests using a rubber hammer
- balance and coordination tests — heel-to-toe walking, heel-to-shin movements; balance with feet together and eyes closed; rapid alternating movements such as touching the finger to the nose with eyes closed
- sense of touch tests using a sharp object and cotton ball or paint brush
- sense of smell tests with various odors
- facial muscle tests — smiling, grimacing
- tongue movement, gag reflex tests
- head movement tests
- mental status tests — i.e. stating the current time and date, naming the current President
- abstract thinking tests — i.e. defining the meaning of "a stitch in time saves nine"
- memory tests — i.e. repeating a list of objects, describing the food you ate at yesterday's breakfast, what occurred last Thanksgiving

If the results of your neurological examination lead the doctor to suspect you have a brain tumor, a scan will be ordered, or you might be referred to a neurological specialist for additional testing. Those tests might include the following scans, xrays, or laboratory tests.

Scans

Scans take the place of conventional x-rays, which do not show tumors located behind the bones of the skull or spine. Different types of imaging devices are used to perform scans. The most common scans for diagnosis and follow-up are Magnetic Resonance Imaging (MRI) and Computerized Tomography (CT).

Both MRIs and CTs use computer graphics to create an image of the brain. An injection of a special contrast material (dye) to make abnormal tissue more obvious is usually given during the scan. The contrast materials concentrate in diseased tissues in greater quantity than in healthy tissues. That concentration is due to the leakiness of blood vessels in and around brain tumors. Contrast materials highlight abnormalities such as tumors.

Small tumors, tumors next to bone, brain stem tumors, low grade and metastatic tumors might be imaged better by MRI than CT. CT is more effective at showing calcification and bony erosion. Your doctor determines which scan/s to use.

CT SCAN

This scan combines an x-ray device with a computer. For some types of tumors, CT images are obtained both with and without contrast enhancement to provide important additional information.

If contrast is used, it is usually injected after a few pictures are taken. The patient lies on a table that slides into a doughnut-shaped opening. The CT scanner circles the head so x-rays penetrate the brain from many directions. Absorption of the x-rays varies with the type of tissue penetrated. Thousands of thin cross-section readings are fed into the computer, which transforms the information into a picture.

MRI SCAN

The MRI is a tunnel-shaped piece of equipment. Some pictures are taken prior to contrast injection. If contrast is to be used, it is injected prior to the completion of the scan. The patient lies on a table that slides into the tunnel. Inside the scanner, a magnetic field surrounds the head. A radio frequency pulse is introduced to the area. No x-rays are used. The magnetic field causes atoms in the brain to change direction. The radio frequency pulse causes another change of direction. When the pulse stops, the atoms relax and return to their original position. During relaxation, the atoms give off energy in differing amounts and at different intervals of time. Antennas pick up these signals and feed them into a computer, which assembles a picture. Because different atoms have their own characteristic radio signals, the computer can distinguish between healthy and diseased tissue.

Patients with some cardiac monitors, pacemakers, or some types of surgical clips cannot undergo MRI scanning because of the magnetic fields. For those who are claustrophobic, sedation or "open" MRI scanners may be an option.

OTHER CT OR MRI BASED SCANS

Computer technology advances have made possible the development of new methods for using existing scanning equipment. These new methods provide advanced tools for diagnosis.

Most of these new tools measure the rate of blood flow into the brain. A contrast dye is given to the patient by intravenous (IV) infusion. The scanner begins taking pictures as soon as the dye is given. Using computerized timing, a succession of rapid pictures can be imaged, tracing the path of blood flow into the brain and to the brain tumor. These techniques are also used to scan spinal cord tumors.

These new methods are collectively called hemodynamic imaging. The information gathered can be converted into images or graphed into charts. Several different types of scanning equipment are used to produce these images: CT, MRI, PET, and SPECT.

Dynamic CT and Dynamic MRI
The CT or MRI is combined with the ability to measure the uptake of the contrast dye from the time it begins to flow from the IV. Dynamic scans are especially useful in showing the growth of new blood vessels around a tumor.

MRI SCAN

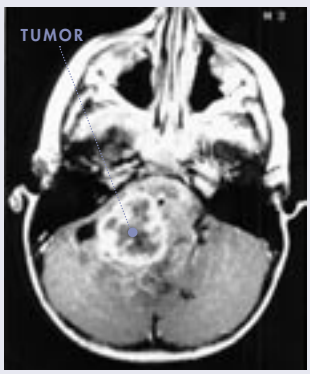

This MRI scan shows an ependymoma.

Scan courtesy of Dr. Regina Jakacki

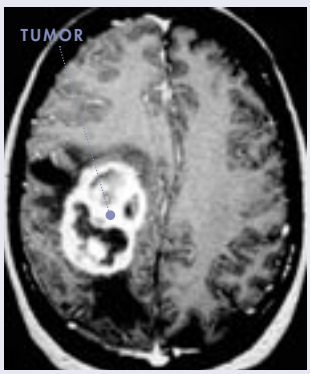

MRI scan of a glioblastoma multiforme.

Scan courtesy of Dr. Jeffrey Bruce

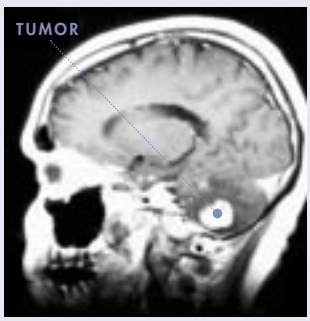

MRI scan of a single breast metastasis in the cerebellum.

Scan courtesy of Dr. Deborah Heros

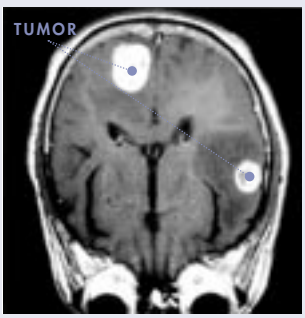

MRI scan of multiple brain mestastases.

Scan courtesy of Dr. Raymand Sawaya

Functional MRI
(also called Echoplanar, "Real Time" or Fast MRI)
This technique produces MRI images in a faster sequence than traditional MRIs. The increased speed permits the tumor's use of oxygen to be depicted. Functional MRI may be useful prior to or during surgery to show the specific areas of the brain that control speech, movement, and memory so they can be avoided.

Flow Sensitive MRI (FS MRI)
This type of scan combines functional MRI with images of cerebrospinal fluid (CSF) flow. FS MRI can be used to show the flow of CSF through the ventricles and spinal cord. It can be useful in planning for the surgical removal of a skull base tumor, spinal cord tumor, or a tumor causing hydrocephalus.

ANGIOGRAPHY AND MRI ANGIOGRAPHY (MRA)

Angiography is used to outline the presence and position of blood vessels in the brain. After injection of a contrast material into a deep artery, x-rays follow its flow through the blood vessels of the brain. MRI angiography, which is less invasive, uses a rapid succession of MRI scans to follow the blood flow, and can be done with or without the injection of contrast dye.

The role of angiography for brain tumors is usually limited to planning the surgical removal of a tumor suspected of having a large blood supply, or tumors growing into an area of the brain with an abundance of blood vessels. At times, angiography can be used as a means of embolizing or closing-off large blood vessels which feed the tumor, making surgery easier.

MRS (MAGNETIC RESONANCE SPECTROSCOPY)

MRS produces images depicting function rather than shape. The equipment requires a special, highly complex facility.

Capable of measuring some byproducts of living tissue (called metabolites), this non-invasive scanning technique can depict patterns of activity that may be useful in diagnosing specific tumors. MRS may be useful with low grade gliomas, tumors with a large amount of surrounding edema and in differentiating between tumor recurrence and radiation necrosis. This technique may also be valuable in suggesting the degree of malignancy. MRS and PET are complementary tools for metabolic imaging.

PET (POSITRON EMISSION TOMOGRAPHY, FDG-PET)

PET is not routinely used for diagnosis but it can complement scanning information by suggesting tumor grade. It can also be used to try to distinguish between recurrent tumor versus cells killed by radiation (necrosis) versus scar tissue.

In a PET scan, a low-dose of radioactive sugar (called FDG) is injected into the patient. The PET scanner rotates around the patient's head, detecting the amount of radioactive sugar taken up by various parts of the brain. A growing tumor consumes sugar at a high rate; radiation necrosis or scar tissue consumes almost no sugar.

Measurements of brain activity (determined by concentrations of the sugar) feed into a computer, which produces a color-coded moving picture or a black and white image of the brain as it converts sugar into energy. The use of PET had been limited because it requires complex equipment. There also can be false negatives and positives. An increasing number of facilities now offer or can arrange PET scanning. Truck-mounted mobil PET and PET/CT scanners are also bringing this technology into the community.

SPECT (SINGLE PHOTON EMISSION COMPUTERIZED TOMOGRAPHY)

SPECT is not routinely used in the initial diagnosis of a brain tumor, but might complement information obtained from other scans.

A SPECT scan is similar to PET. Radioactive tagged materials taken up by the brain are used. A special camera measures the rate of emission of the material as it moves through the brain. Images are generated from that information. After MRI or CT, this test might be helpful in distinguishing between low-grade and high-grade tumors, or between recurrent tumor and necrosis.

MEG (MAGNETOENCEPHALOGRAPHY)

The MEG scan measures the magnetic fields created by nerve cells as they produce the small electrical currents used for neurotransmission. No physical contact is required to record the signals.

The device looks like an old-fashioned hair dryer. When the patient moves, a computer-generated image shows which brain area is responsible for directing the motion.

MEG is used in combination with information from other types of scans to determine the function of specific areas of the brain. However, MEG scanning is available at a very limited number of facilities.

X-Rays

Plain skull x-rays are usually not necessary for diagnosis except to help determine if calcification or bony erosion is present. Slow growing tumors can cause calcification; increased intracranial pressure might cause erosion. X-rays might be used to determine the condition of the skull adjacent to meningeal and skull base tumors.

A radiologist interprets the computer images produced by scans and x-rays. The pictures help establish a tentative diagnosis and might suggest the type of tumor — but they are not definitive. Only examination of a sample of tumor tissue under a microscope provides an exact diagnosis.

Laboratory Tests

LUMBAR PUNCTURE (SPINAL TAP)

Lumbar puncture is used to obtain a sample of cerebrospinal fluid (CSF). This procedure is usually avoided if there is any indication of increased intracranial pressure because of the risk of the brain's bulging through an opening in a membrane, muscle, or bone (herniation).

The sample of CSF is examined in a laboratory to determine if tumor cells, infection, protein, or blood is present. This information is particularly helpful in diagnosing primary CNS lymphoma, a pineal region or meningeal tumor. After surgery, the presence of tumor cells in the CSF indicates tumor spread. That information is used for tumor staging and helps the doctor determine appropriate treatment choices.

The CSF is also examined for the presence of known tumor markers, substances which indicate the presence of a tumor.

Unfortunately, most primary brain tumors have no tumor markers. At this time, only some germ cell tumors are known to produce those substances. Known germ cell tumor markers are:

AFP alpha-fetoprotein

HCG human chorionic gonadotropin

PLAP placental alkaline phosphatase

CEA (carcinoembryonic antigen) is a marker for a tumor of the arachnoid and/or pia mater membranes of the meninges (a leptomeningeal tumor). These are usually metastatic tumors.

If they are present, tumor markers are helpful in the diagnosis and follow-up evaluation of germ cell and metastatic brain tumors only.

MYELOGRAM

Lumbar puncture is used to inject a special dye before a myelogram. The patient is then tilted to allow the dye to mix with the spinal fluid. This test is used primarily to diagnose a spinal tumor and obtain pre-operative information for spinal tumor surgery.

Spinal MRI has replaced myelography for many conditions.

EVOKED-POTENTIALS

Evoked-potential testing uses small electrodes to measure the electrical activity of a nerve. This test is particularly useful in detecting a vestibular schwannoma (acoustic neuroma).

Evoked-potentials can also be used to monitor neurological function during the surgical removal of a tumor.

AUDIOMETRY

This hearing test is useful in the diagnosis of a cerebellopontine angle tumor such as the vestibular schwannoma (acoustic neuroma).

ENDOCRINE EVALUATION

Measurements of hormone levels in samples of blood and urine are used, along with scans, to diagnose a pituitary or hypothalamic tumor.

Hormone	Responsible for...	Normal Blood Levels in Adults
ACTH adrenocorticotropic hormone	Controls the production of cortisol — a natural steroid needed to control blood pressure, sugar and salt levels	9 to 52 pg/ml
GH growth hormone	Controls bone growth; height; body proportion in the extremities and jaw	0 to 3 ng/ml
PRL prolactin	Controls milk production in women, impacts sex drive and sperm counts in men	Males and non-pregnant women: 0 to 20 ng/ml In pregnancy: 10 to 300 ng/ml
TSH thyroid stimulating hormone	Controls thyroid functions such as metabolism, heart rate and appetite	0.2 to 4.7 mcU/ml

PERIMETRY

This technique measures the size of visual fields. The information obtained might be useful in diagnosing a tumor in the area of the optic chiasm, such as a pituitary tumor.

Biopsy

A biopsy is a surgical procedure in which a small amount of tumor tissue is removed. The neurosurgeon submits the tumor tissue to a pathologist for study and analysis. Only then is a tissue diagnosis possible.

A biopsy can be performed as part of the surgery to remove the tumor, or as a separate diagnostic procedure.

For areas considered to be inoperable, the surgeon is often able to perform a needle biopsy through a small hole drilled into the skull called a burr hole. A narrow, hollow needle is inserted through the burr hole. Tumor tissue is removed from the core of the needle.

Stereotaxic biopsy is a computer directed needle biopsy. The computer, using information from a CT or MRI scan, provides precise information about a tumor's location and its position relative to the many structures in the brain.

Stereotactically-guided equipment might be moved into the burr hole to remove a sample of the tumor. This is called a closed biopsy.

When a biopsy is not performed, diagnosis relies solely on the interpretation of other test results.

About Follow-Up Testing

At intervals during and after treatment, your doctor will probably order some of the same tests you took when your tumor was first diagnosed.

These tests measure the effectiveness of the treatment and monitor for possible recurrence. Other tests help evaluate your medication.

Your doctor will tell you when your next scans or tests should be done. If you don't have this information, call your doctor's office and ask. Follow-up is as important as treatment.